HEPATOBİLİYER HASTALIKLARDA İLERİ ENDOSKOPİK UYGULAMALAR

ERCP

Prof Dr Erkan Parlak

Sakarya Üniversitesi Tıp Fakültesi, Gastroenteroloji Kliniği

Sakarya

TÜRK KARACİĞER VAKFI
(www.tkcv.org)

AZERBAYCAN
TIP ÜNİVERSİTESİ

3 TÜRKİYE-AZERBAYCAN ORTAK HEPATOLOJİ KURSU
29-30 Eylül 2017, İstanbul

İlk endoskopik kolanjiografi, 1968: McCune

İlk sfinkterotomi,

1974: Classen ve Kawai

TYİH,

1975: Burhan Şahin

MAVİ BÜLTEN — CİLT — 9 — SAYI : 1 — 1977

PANKREAS HASTALIKLARI VE İNTRAHEPATİK KOLESTAZDA ENDOSKOPİK RETROGRAD KOLANJİOPANKREATOGRAFİ (E.R.C.P.)

Dr. Burhan ŞAHİN(*)
Dr. Turhan CUMHUR(***)
Dr. Gönül GÜRKAYNAK(*****)
Dr. Ali GÖKÖZ(**)
Dr. Leziz ONARAN(****)
Dr. Gülay TEMUÇİN(******)

Pankreas ve safra yolları hastalıklarının tanısında önemli bir gelişme sağlayan E.R.C.P. yı bizde kliniğimizde uygulamaktayız.

Materyal : 19 sarılıklı ve 12 pankreas patolojisi düşünülen toplan 31 hastaya E.R.C.P. yapıldı.

Metod : Muayeneler televizyonlu röntgen cihazı yandan görüşlü duodenoskop ve teflon ktanül kullanılarak yapıldı. Sedasyon için 10 mgr. diazem amp. duodenal hipotoni için Buscopan ve opak madde olarak % 76 lık Ürografin kullanıldı.

Teknik : Sedasyonu takiben boğaz anestezisi yapıldı. Hasta sol yanı üzerine röntgen masasına yatırıldıktan sonra duodenoskop yutturu lur. Mide incelendikten sonra pilor geçilerek bulbusa girilir. Bulbus tetkikinden sonra duodenoskopun 90 - 180° lik Clock wise rotasyonu ve distal ucun up pozisyonu ile superior duodenal açı bulunur ve ikinci kıt'aya girilir. Bu esnada hastaya 40 mgr. Buscopan yapılır. daha sonra duodenoskopa 90 - 180° lik vounter clock wise rotasyonu yaptırılarak papilla aranır ve tüm görüş alanının ortasına getirilir.

(*) T.Y.İ.H. G.E. Kliniği Baş Asistanı
(**) T.Y.İ.H. G.E. Kliniği Asistanı
(***) T.Y.İ.H. Rad. Kliniği Şef Muavini
(****) T.Y.İ.H. G.E. Kliniği Şefi
(*****) T.Y.İ.H. G.E. Kliniği Asistanı.
(******) T.Y.İ.H. G.E. Kliniği Şef Muavini

ERCP ENDİKASYONLARI

Biliyer

...Safra yolu taşları
...Safra kaçakları
...Safra yolu benign darlıkları
...Safra yolu malign darlıkları
...Diğer endikasyonlar (konjenital hastalıklar vb)

Pankreatik

...

ERCP - tanımlar

...Kanülasyon ve kolanjiografi
...Endoskopik sfinkterotomi
...Dilatasyon
...Taş çıkartılması
...Drenaj
  * Stent
  * NBD
...Örnek alma
...Kolanjioskopi

ERCP - tanımlar

...Kanülasyon ve kolanjiografi
...Endoskopik sfinkterotomi
...Dilatasyon
...Taş çıkartılması
...Drenaj
  * Stent
  * NBD
...Örnek alma
...Kolanjioskopi

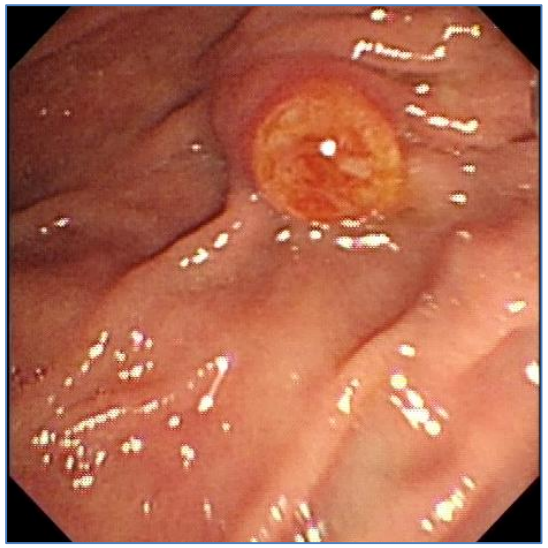

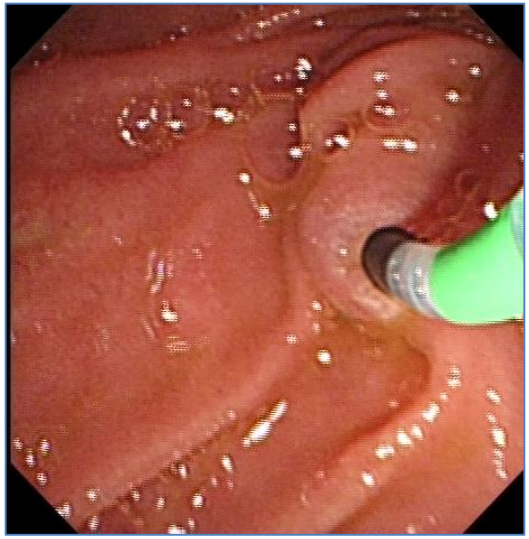



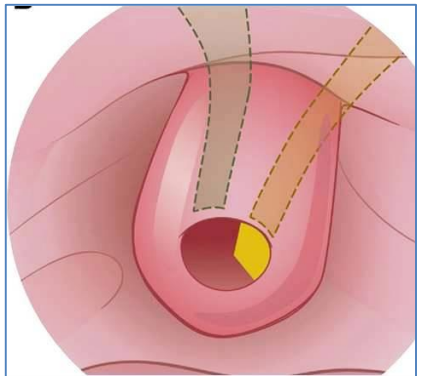

ERCP - tanımlar

...Kanülasyon ve kolanjiografi
...Endoskopik sfinkterotomi
...Dilatasyon
...Taş çıkartılması
...Drenaj
  * Stent
  * NBD
...Örnek alma
...Kolanjioskopi

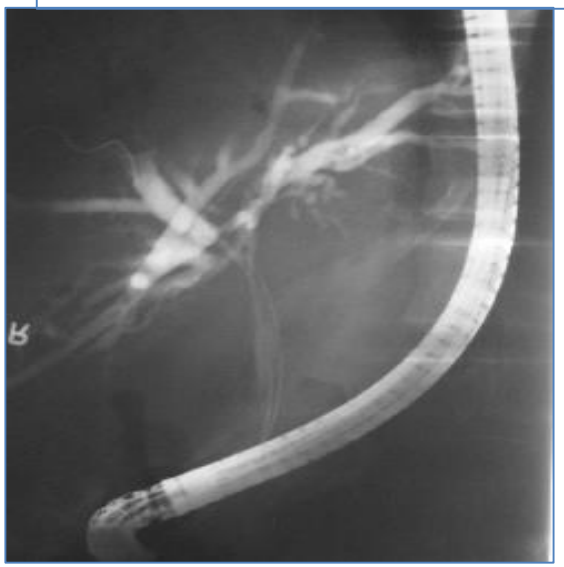

ERCP - tanımlar

...Kanülasyon ve kolanjiografi
...Endoskopik sfinkterotomi
...Dilatasyon
...Taş çıkartılması
...Drenaj
  * Stent
  * NBD
...Örnek alma
...Kolanjioskopi

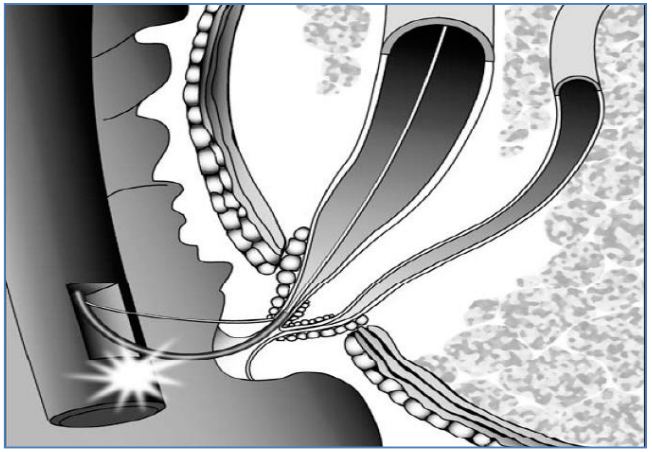

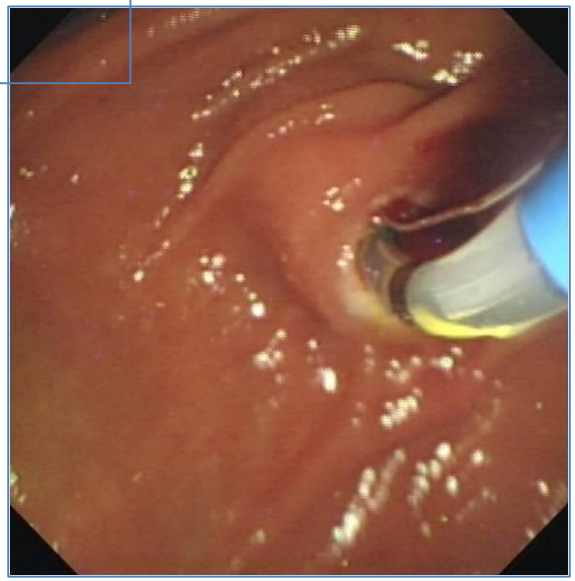

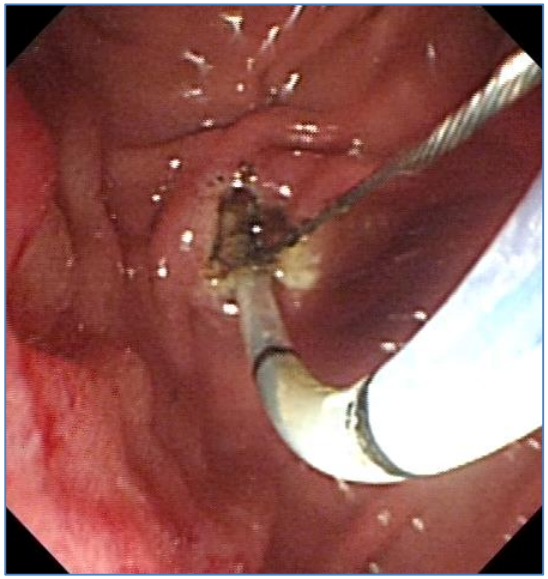

ERCP - tanımlar

...Kanülasyon ve kolanjiografi
...Endoskopik sfinkterotomi
...Dilatasyon
...Taş çıkartılması
...Drenaj
  * Stent
  * NBD
...Örnek alma
...Kolanjioskopi

BALON

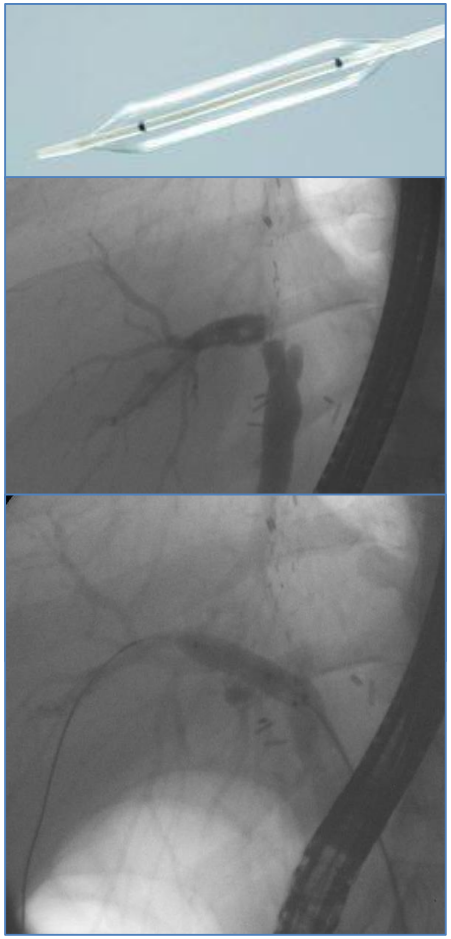

SOEHENDRA

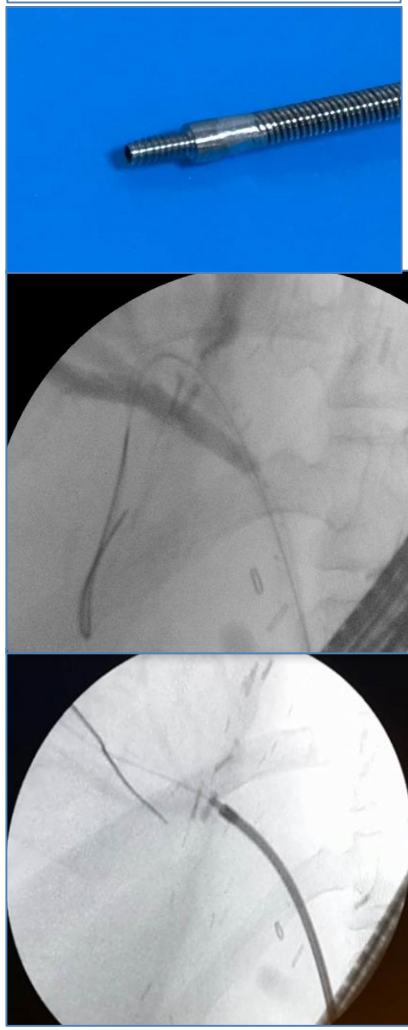

BUJİ

ERCP - tanımlar

...Kanülasyon ve kolanjiografi
...Endoskopik sfinkterotomi
...Dilatasyon
...Taş çıkartılması
...Drenaj
  * Stent
  * NBD
...Örnek alma
...Kolanjioskopi

PAPİLLAYI HAZIRLAMA

ES

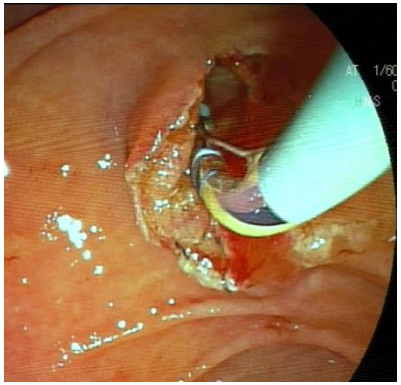

balon dilatasyonu

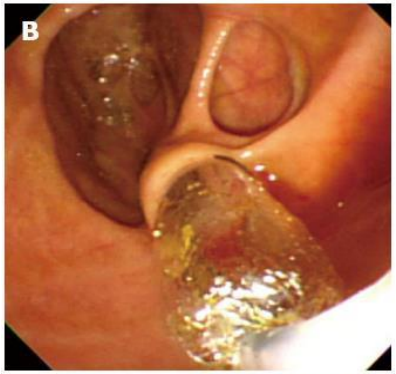

ES + 'large' balon dilatasyonu

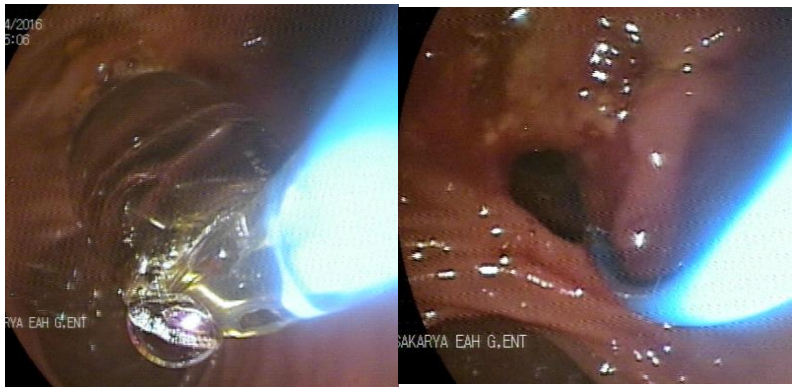

ERCP - tanımlar

...Kanülasyon ve kolanjiografi
...Endoskopik sfinkterotomi
...Dilatasyon
...Taş çıkartılması
...Drenaj
  * Stent
  * NBD
...Örnek alma
...Kolanjioskopi

BALON

BASKET

ERCP - tanımlar

...Kanülasyon ve kolanjiografi
...Endoskopik sfinkterotomi
...Dilatasyon
...Taş çıkartılması
...Drenaj
  * Stent
  * NBD
...Örnek alma
...Kolanjioskopi

PLASTİK STENT

Polietilen
Teflon
Poliüretan

5.0-11.5 F

5-18 cm

Amsterdam tip
Single pigtail
Double pigtail



7 F….2 ay
10 F….3-6 ay
(10 F iç çapı: 3.3 mm (0.131 inch)

TANIMLAR -Mültipl plastik stent (MPS)

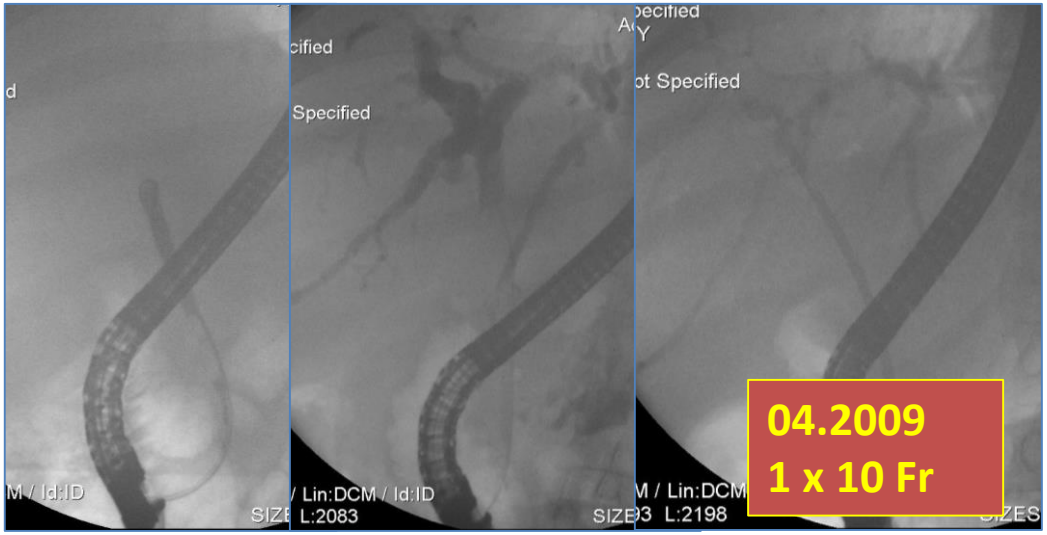

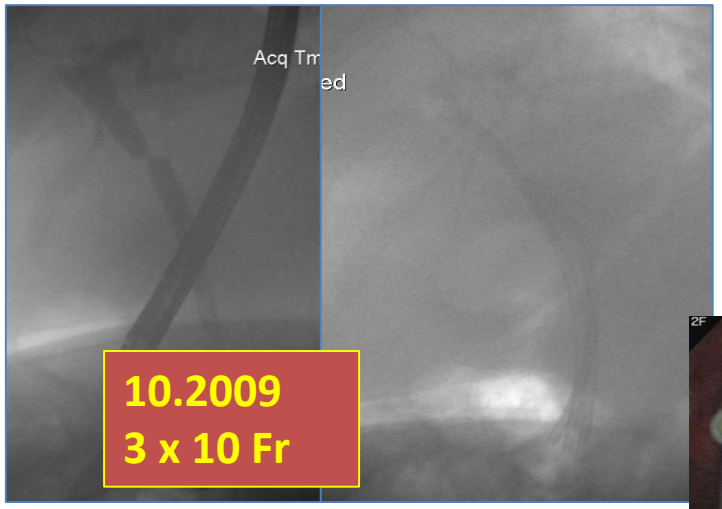

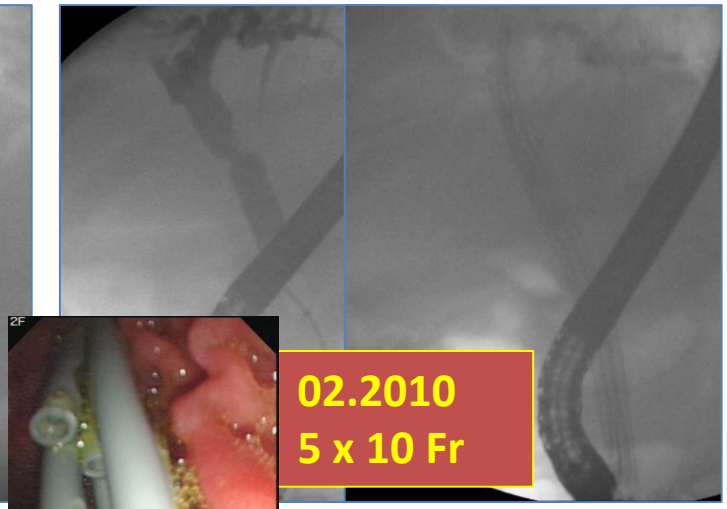

METAL STENLER

Uncovered (Uc-SEMS)

Covered silicone membrane, fluorinated ethylene propylene, expanded polytetrafluoroethylene (ePTFE)

…'partially-covered' (Pc-SEMS)

…'fully-covered' (Fc-SEMS)



	KAPSIZ	KAPLI
Tıkanma	'Ingrowth'	'Overgrowth' Debris Çamur
Çıkartılabilme	Hayır	Evet
Migrasyon	Hayır	Evet

METAL STENTS (SEMS)

Paslanmaz çelik
Nitinol (nikel and titanyum)
Platinol (‘’platinum core with nitinol encasement’’)

4-6-8-10 mm
6-12 ay

“Self expandable”





ERCP - tanımlar

...Kanülasyon ve kolanjiografi
...Endoskopik sfinkterotomi
...Dilatasyon
...Taş çıkartılması
...Drenaj
  * Stent
  * NBD
...Örnek alma
...Kolanjioskopi

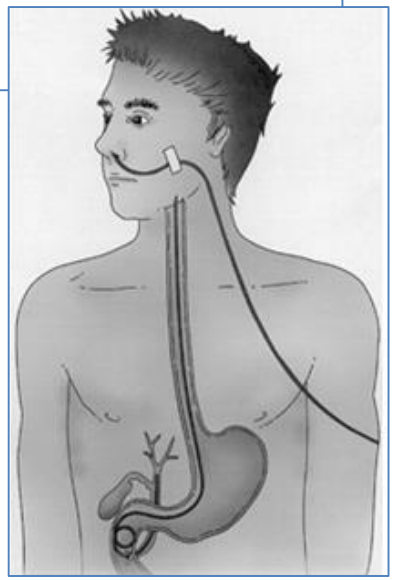

Pigtail



Düz



5 - 7 - 10 F

ERCP - tanımlar

...Kanülasyon ve kolanjiografi
...Endoskopik sfinkterotomi
...Dilatasyon
...Taş çıkartılması
...Drenaj
  * Stent
  * NBD
...Örnek alma
...Kolanjioskopi

Fırça

Forseps

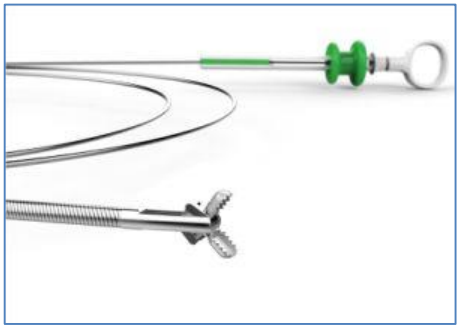

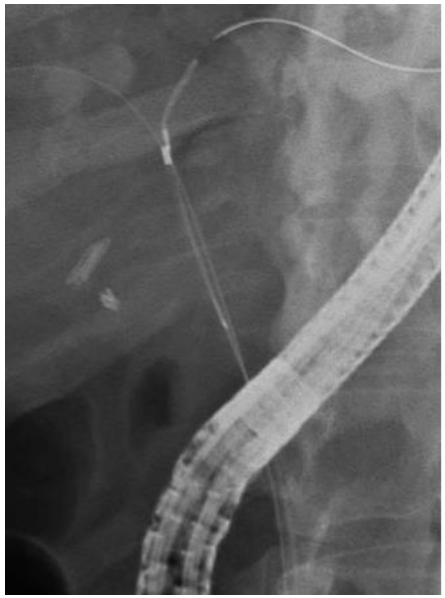

ERCP - tanımlar

...Kanülasyon ve kolanjiografi
...Endoskopik sfinkterotomi
...Dilatasyon
...Taş çıkartılması
...Drenaj
  * Stent
  * NBD
...Örnek alma
...Kolanjioskopi

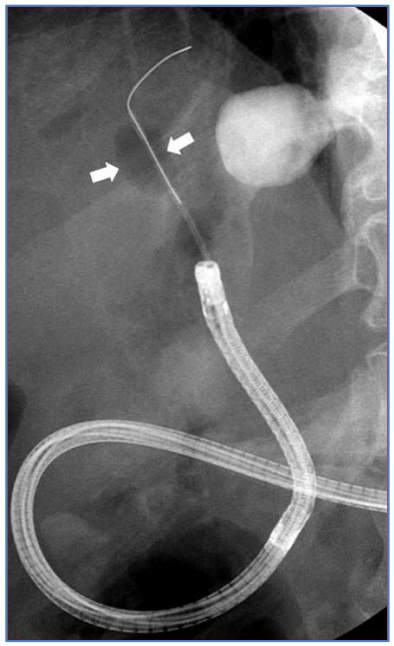

Peroral

TTS
(SpyGlass vb.)

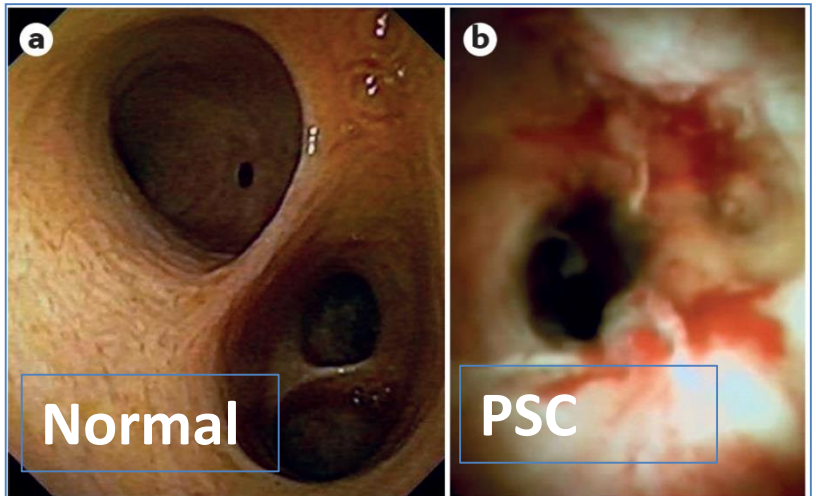

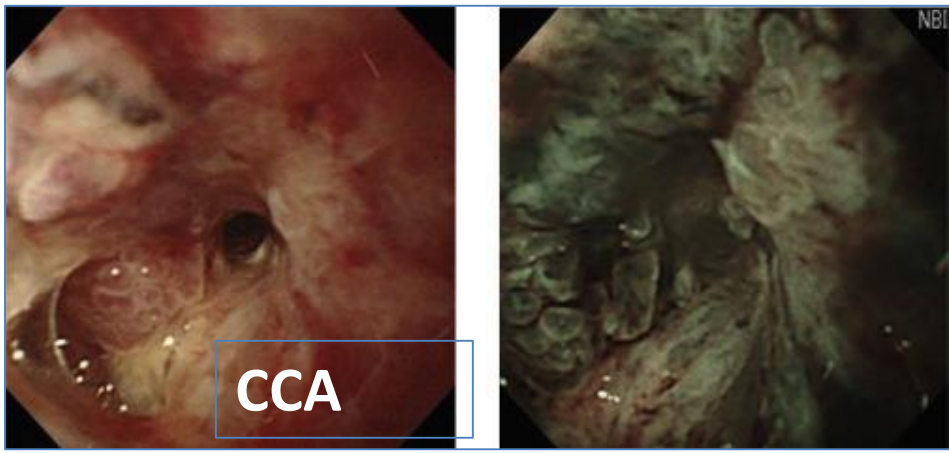

ERCP ENDİKASYONLARI

Biliyer

...Safra yolu taşları
...Safra kaçakları
...Safra yolu benign darlıkları
...Safra yolu malign darlıkları
...Diğer endikasyonlar (konjenital hastalıklar vb)

Pankreatik

...

BALON

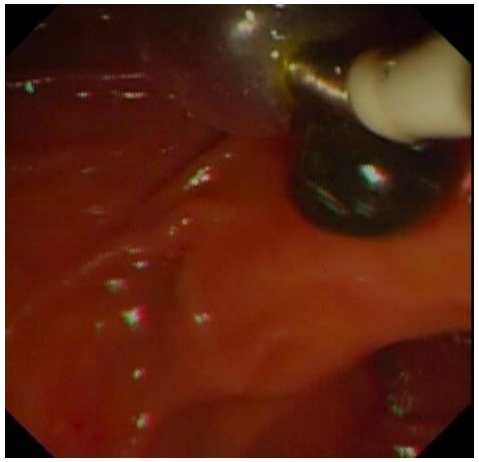

BASKET

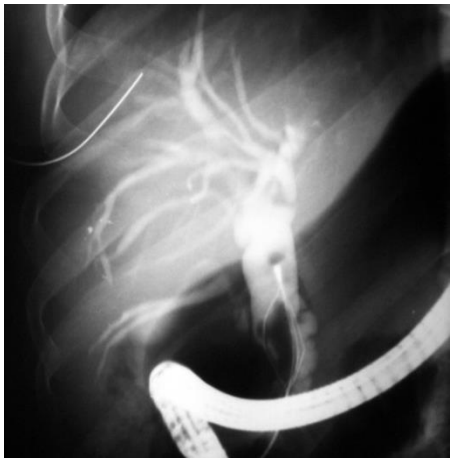

MEKANİK LİTOTRİPSİ

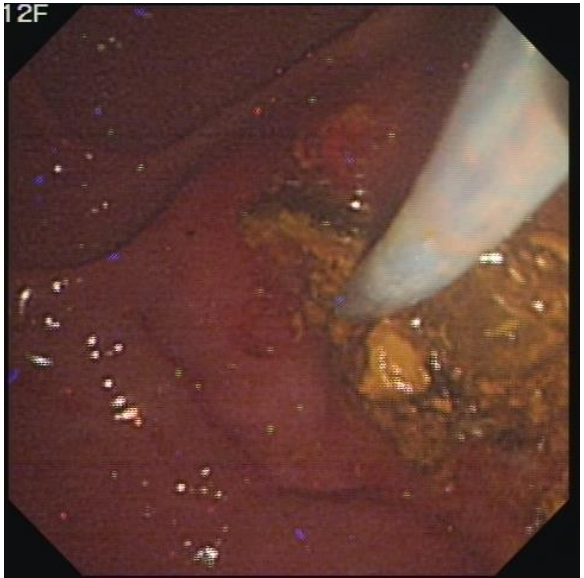

MEKANİK LİTOTRİPSİ

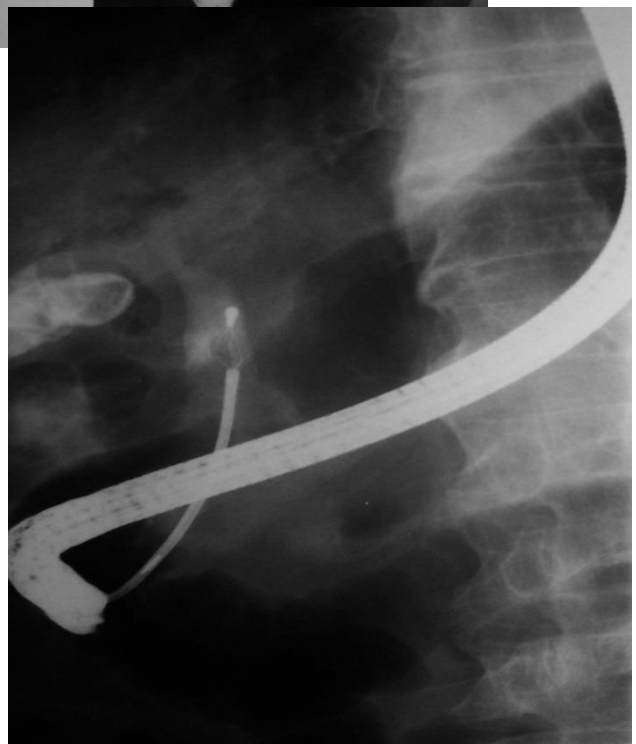

PLASTİK STENT YERLEŞTİRİLMESİ

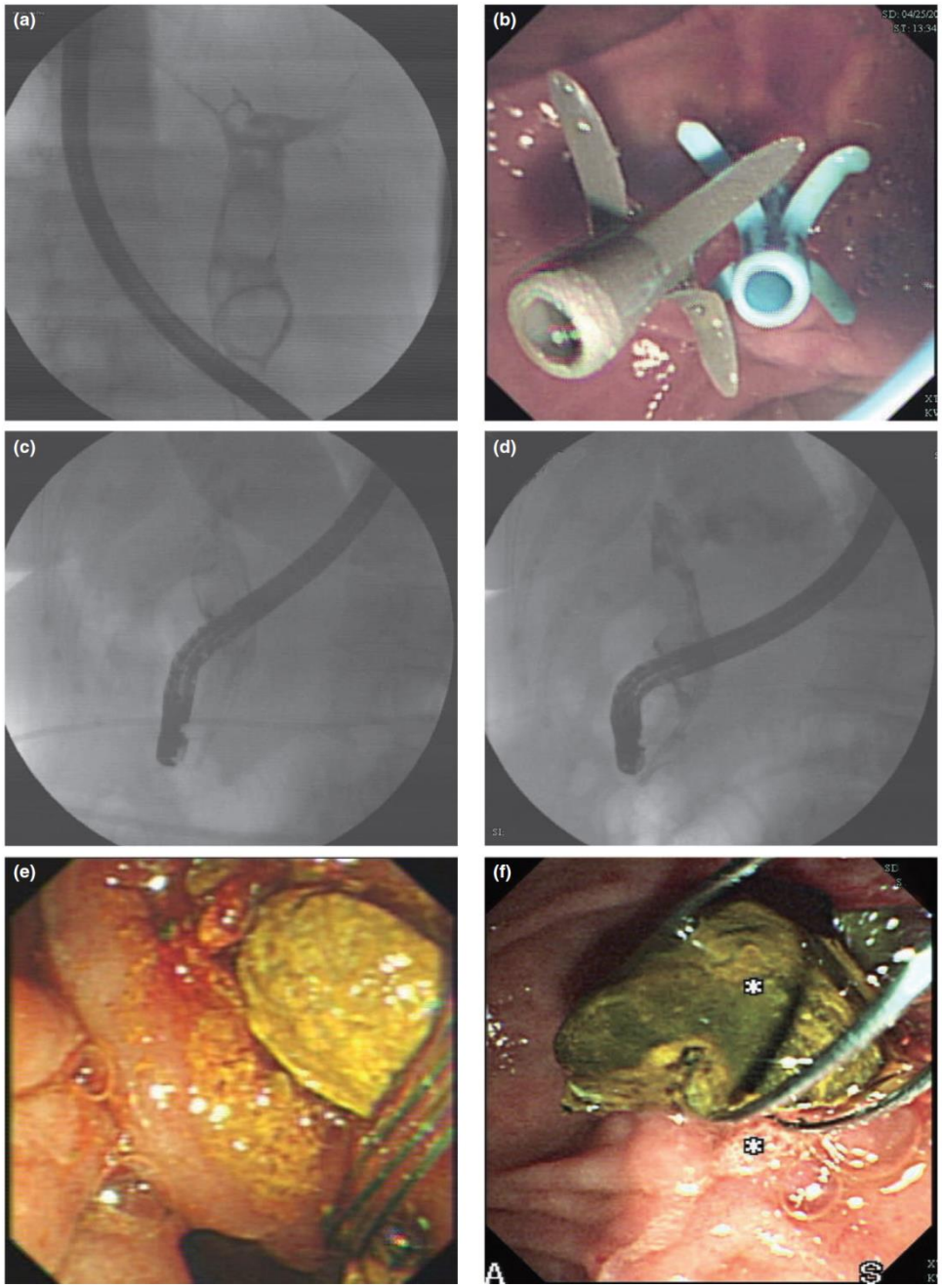

Fig. 1. (a) Multiple large common bile duct (CBD) stones. (b) Double stents in CBD. (c) Endoscopic retrograde cholangiopancreatography of the stent and large CBD stone (23 mm of the stone). (d) Large CBD stone got smaller after 3 months' stenting (16 mm). (e,f) Extraction of CBD stones using basket; 195 × 179 mm (72 × 72 DPI).

Digestive Endoscopy (2011) **23**, 86–90

‘FC-SEMS’ STENT YERLEŞTİRİLMESİ

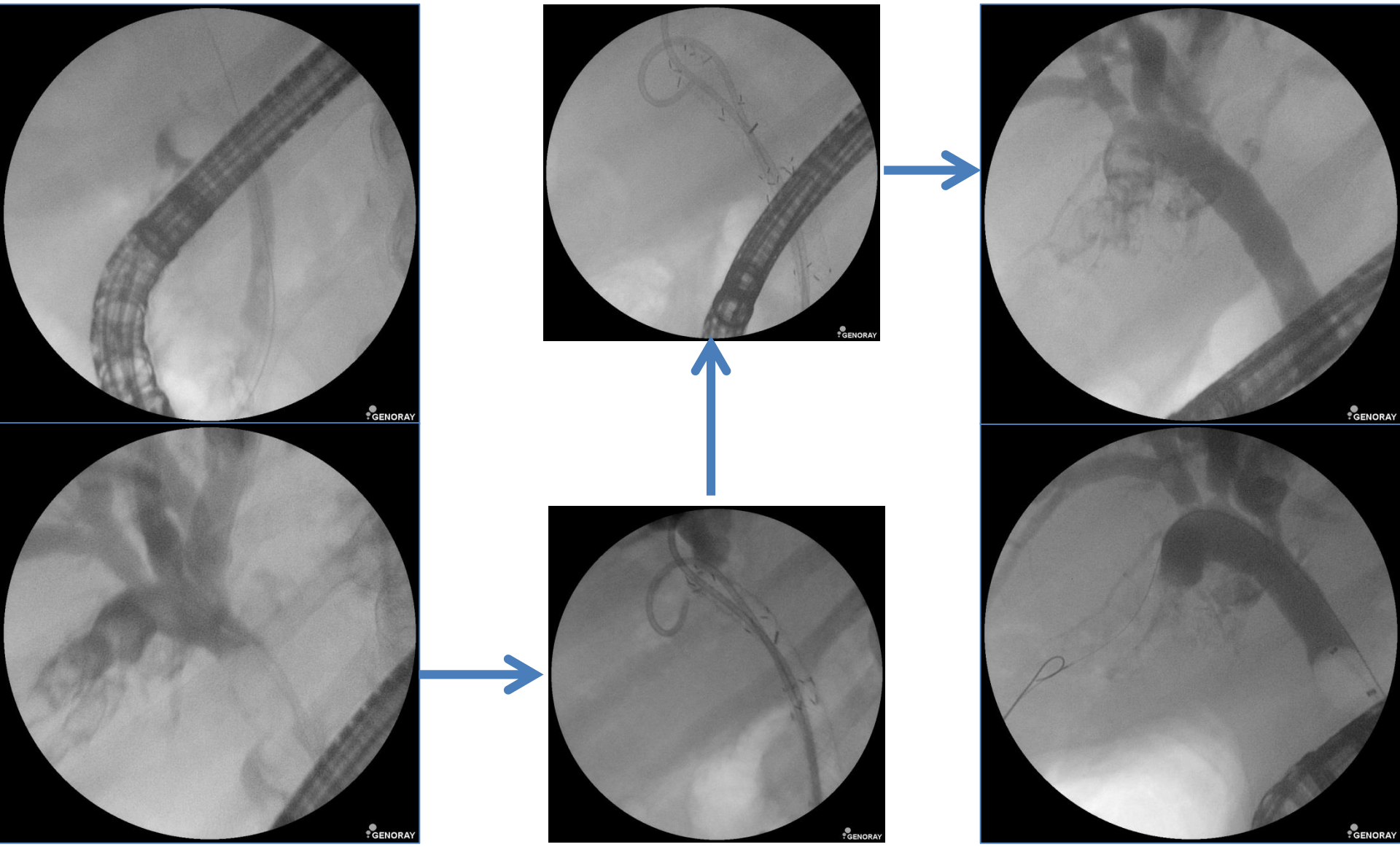

İNTERNAL LİTOTRİPSİ – EHL, LL

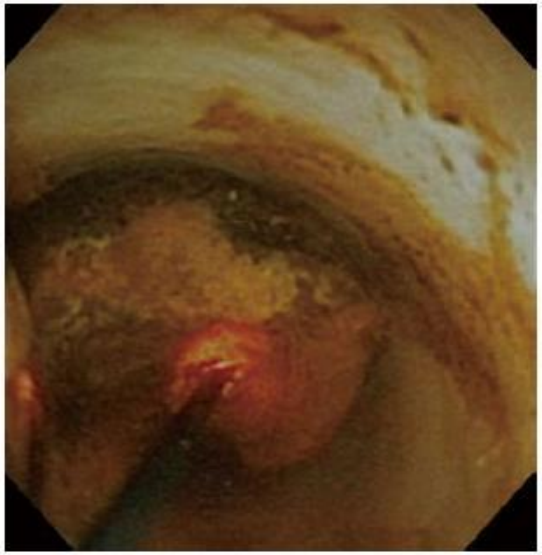

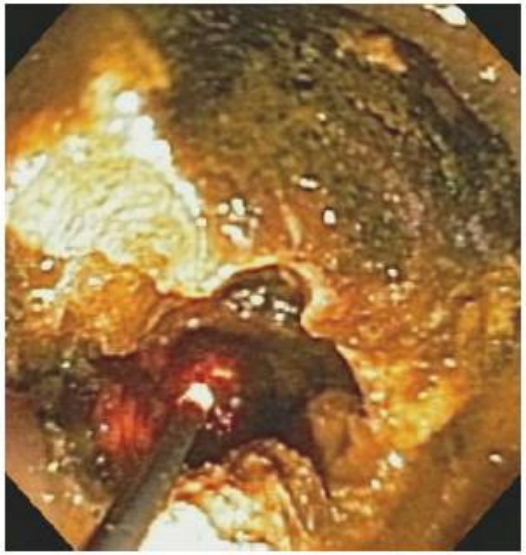

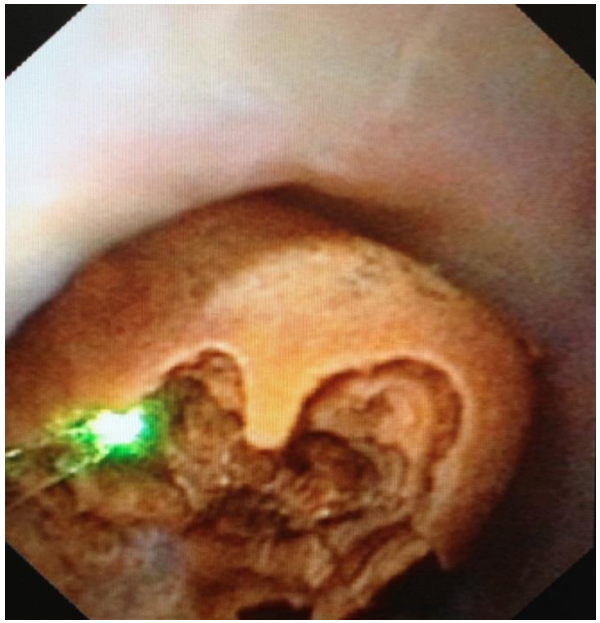

ESWL

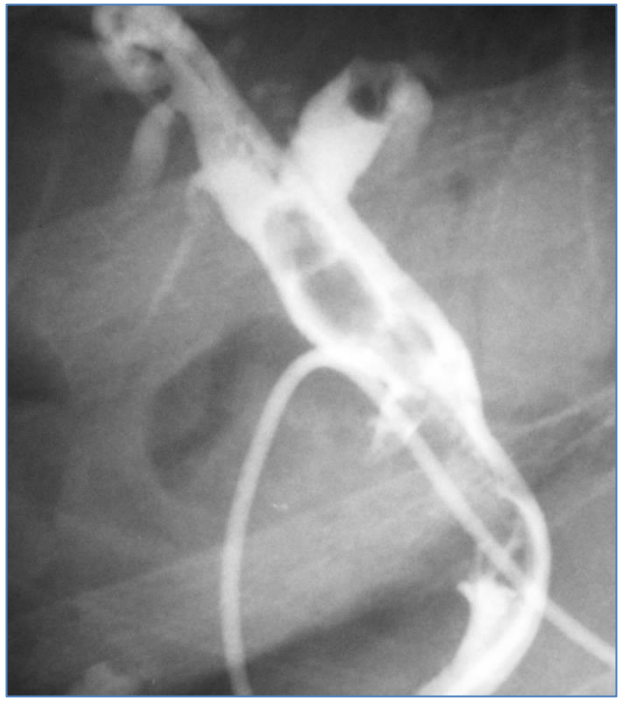

İNTRAHEPATİK TAŞLAR

Predispozan faktörler;

Safra yolu darlığı

Caroli hastalığı

PSC

SSC

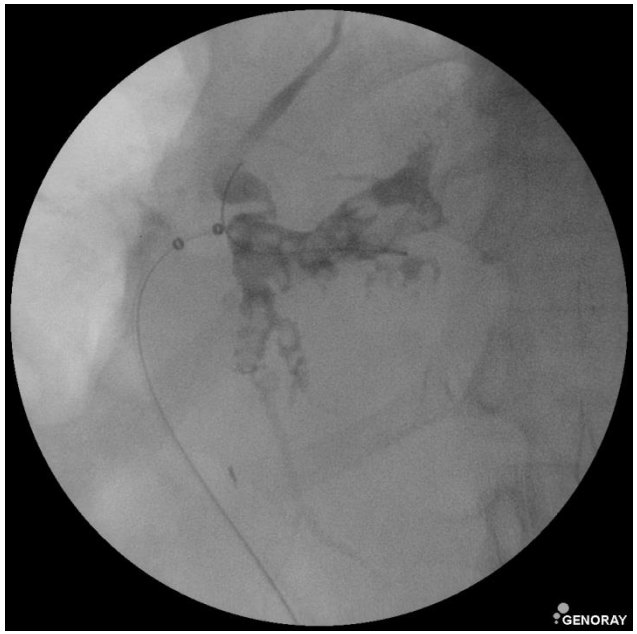

Opere kist hidatik

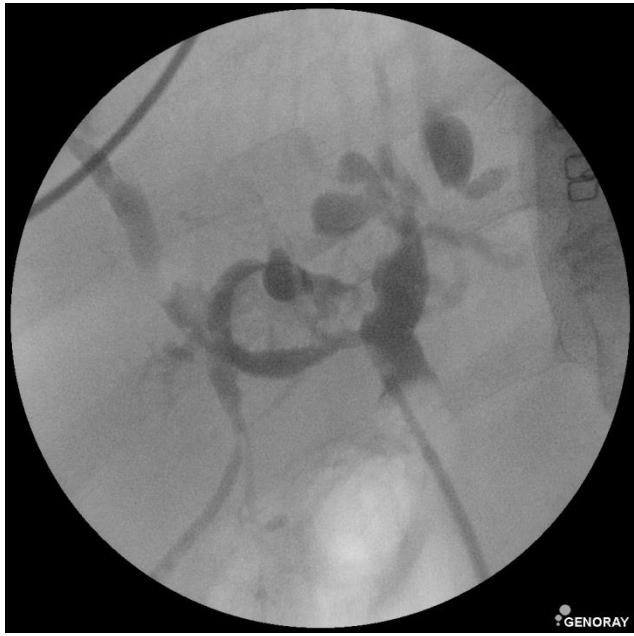

Caroli

İNTRAHEPATİK TAŞLAR

Taş çıkartma yöntemleri

Endoskopik yöntemler

Perkütan yöntemler (perkütan kolanjioskopi ve litotripsi dahil)

Cerrahi rezeksiyon (parsiyel hepatektomi……Tx)

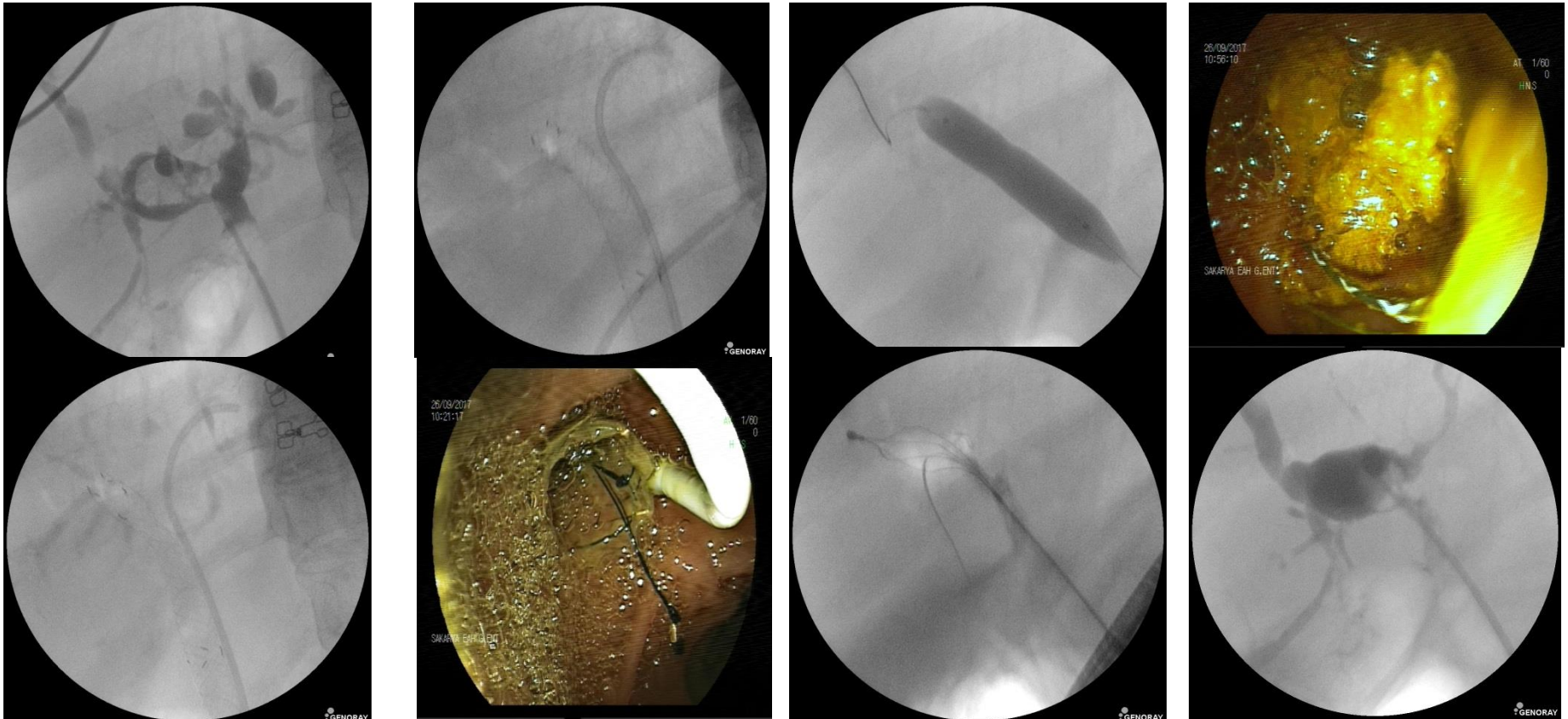

İNTRAHEPATİK TAŞLAR

Taş çıkartma yöntemleri

Endoskopik yöntemler

Perkütan yöntemler (perkütan kolanjioskopi ve litotripsi dahil)

Cerrahi rezeksiyon (parsiyel hepatektomi……Tx)

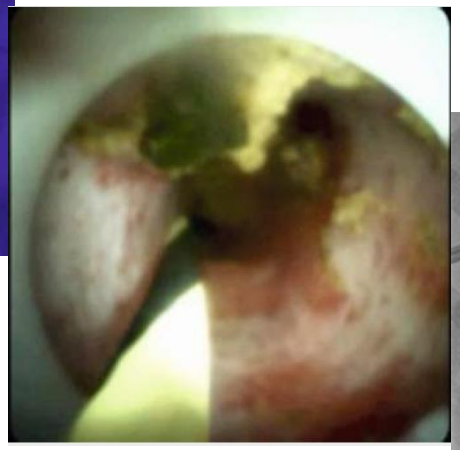

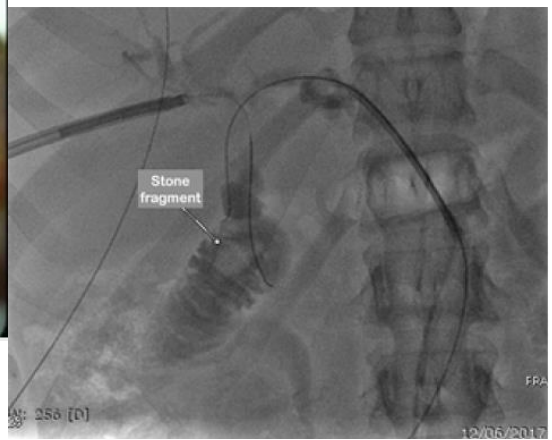

Endoscopy. 2017 Sep 19. doi: 10.1055/s-0043-117943

İNTRAHEPATİK TAŞLAR

Taş çıkartma yöntemleri

Endoskopik yöntemler

Perkütan yöntemler (perkütan kolanjioskopi ve litotripsi dahil)

Cerrahi rezeksiyon (parsiyel hepatektomi……Tx)

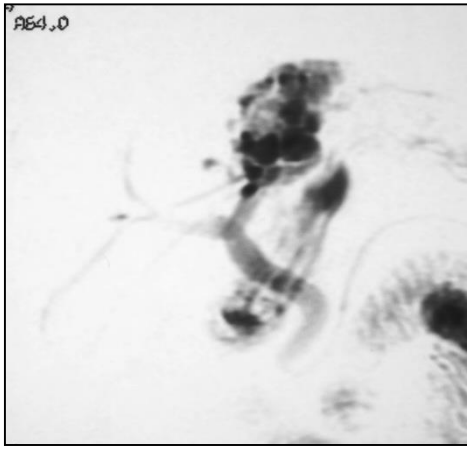

ERCP ENDİKASYONLARI

Biliyer

...Safra yolu taşları
...Safra kaçakları
...Safra yolu benign darlıkları
...Safra yolu malign darlıkları
...Diğer endikasyonlar (konjenital hastalıklar vb)

Pankreatik

...

SAFRA YOLU KAÇAKLARI etyoloji

Kolesistektomi
Major yaralanma
Minör yaralanma (sistik kanal kaçağı, Luschka kaçağı)

Karaciğer cerrahileri
Biliyer rezeksiyon
Biliyer rekonstrüksiyon
Karaciğer rezeksiyonu
Karaciğer transplantasyonu
Kist hidatik cerrahisi

Girişimler
KC biyopsisi
RFA
Embolizasyon
ERCP –tip 3- perforasyonu

Travma (künt veya travmatik)

SAFRA YOLU KAÇAKLARI tedavi

Safra yolu 'UÇ' kaçağı
- Luschka
- Sistik
- Kesi yüzeyi
  ..hepatik rezeksiyon,
  ..kist hidatik,
  ..travmatik
  ..girişimler

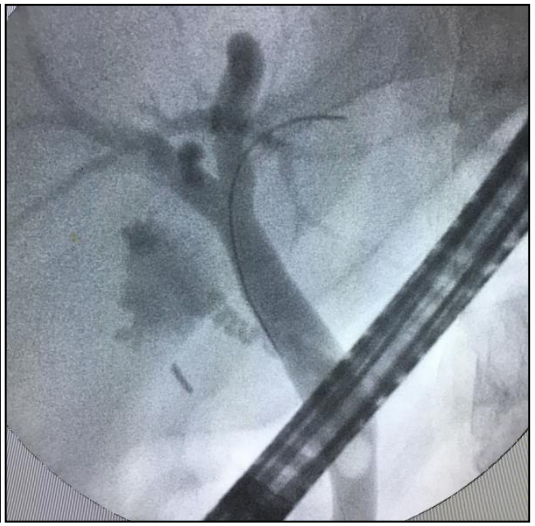

Safra yolu 'YARALANMASI'
- Kolesistektomi
- Kist hidatik
- Biliyer rezeksiyon
- Karaciğer transplantasyonu
- ERCP –tip 3- perforasyonu
- Travmatik

SAFRA YOLU KAÇAKLARI tedavi

Safra yolu 'UÇ' kaçağı
- Luschka
- Sistik
- Kesi yüzeyi
  ..hepatik rezeksiyon,
  ..kist hidatik,
  ..travmatik
  ..girişimler

Amaç;
1.Bilio-duodenal basınç gradientini azaltmak
Yöntem;
- ES
- Plastik stent
- NBD

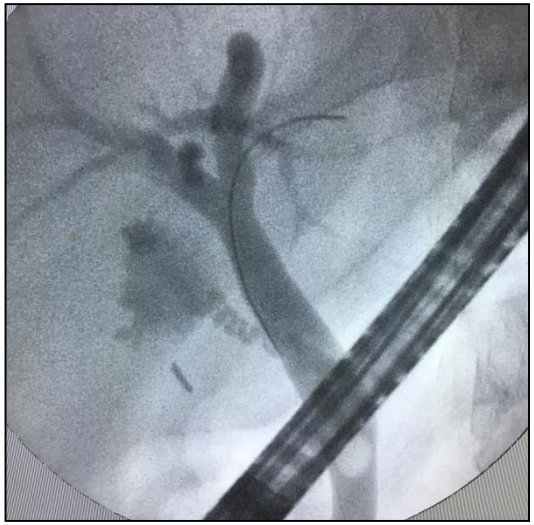

SİSTİK GÜDÜK KAÇAĞI

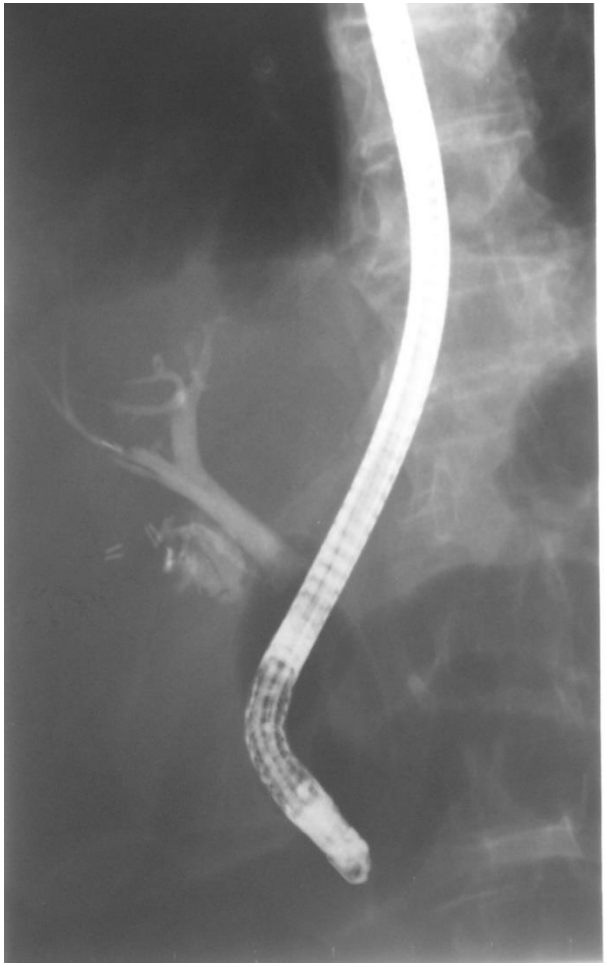

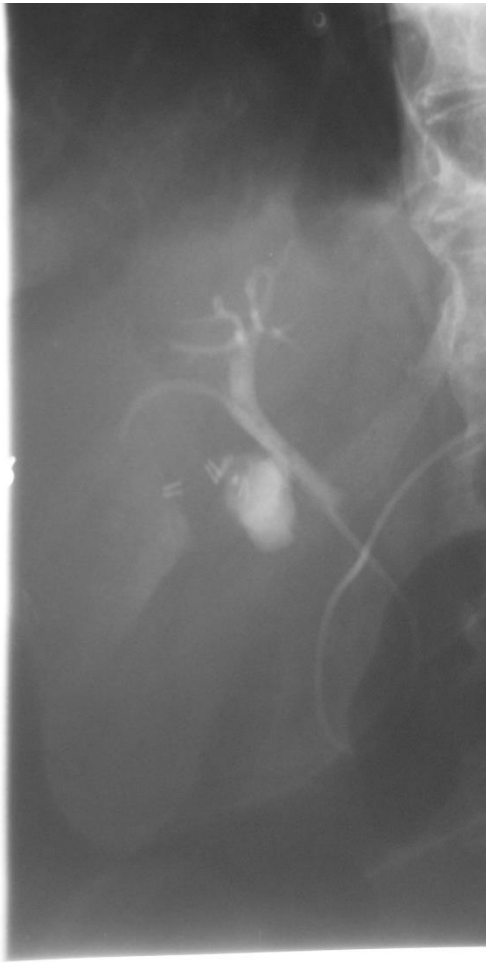

LUSCHKA KAÇAĞI

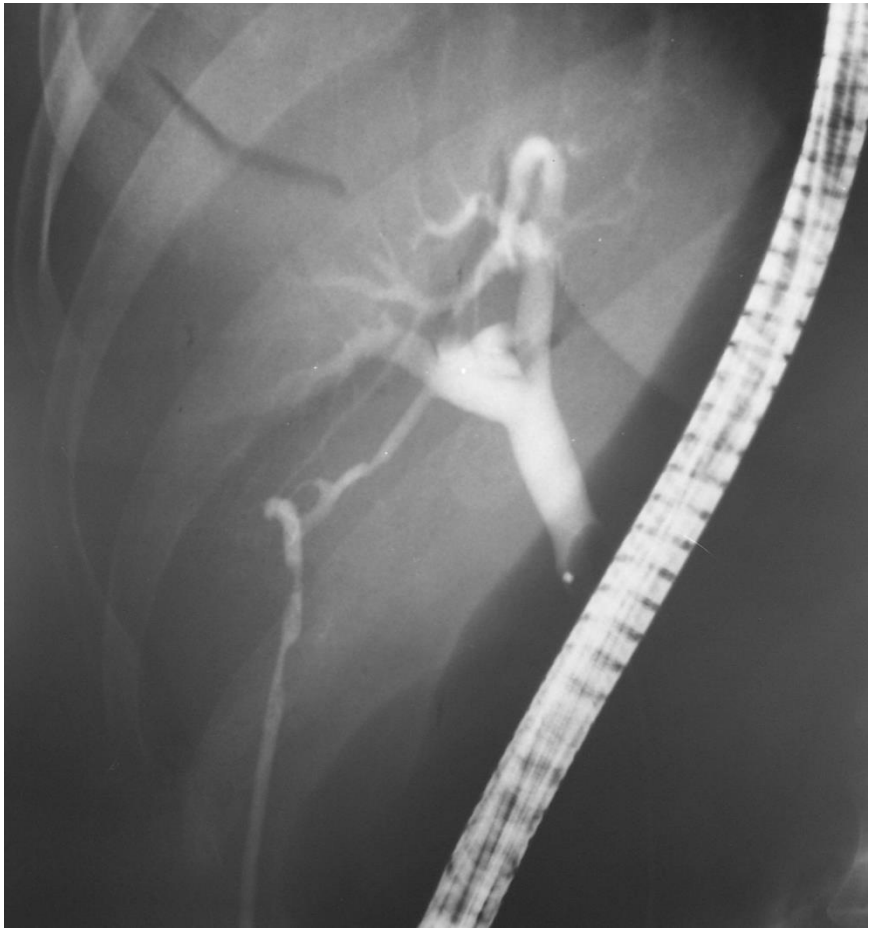

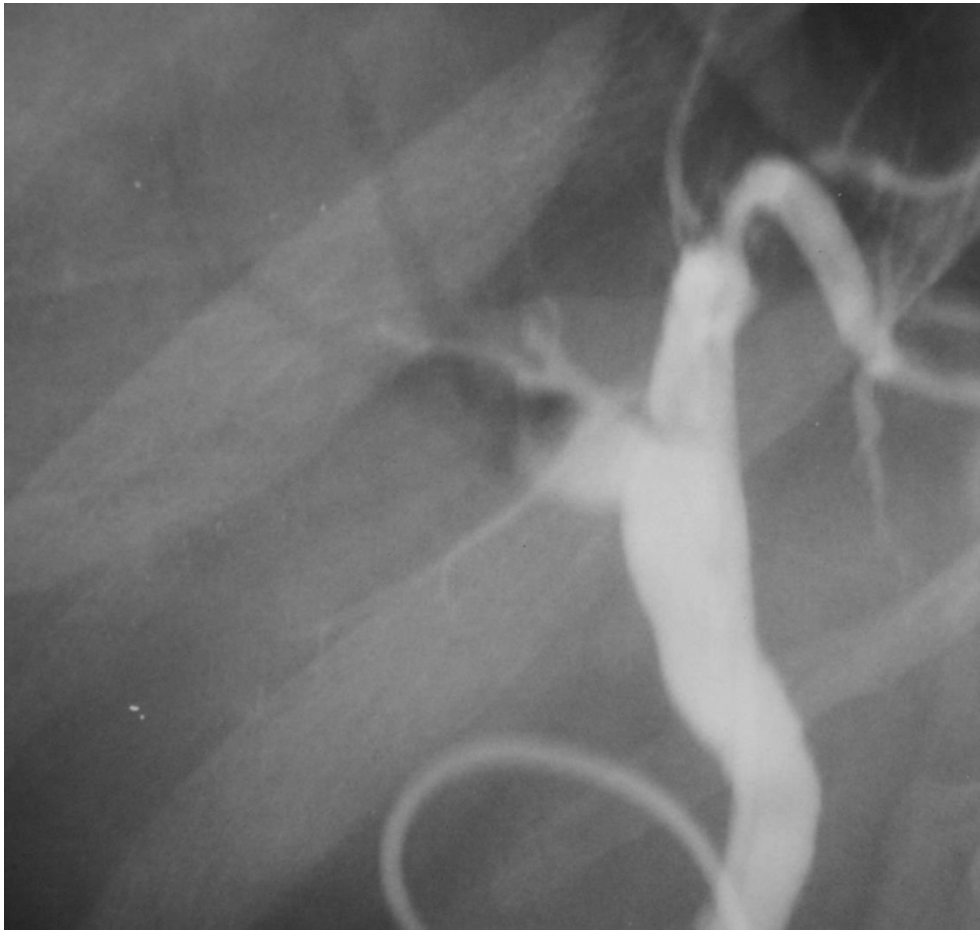

OPERE KİST HİDATİK

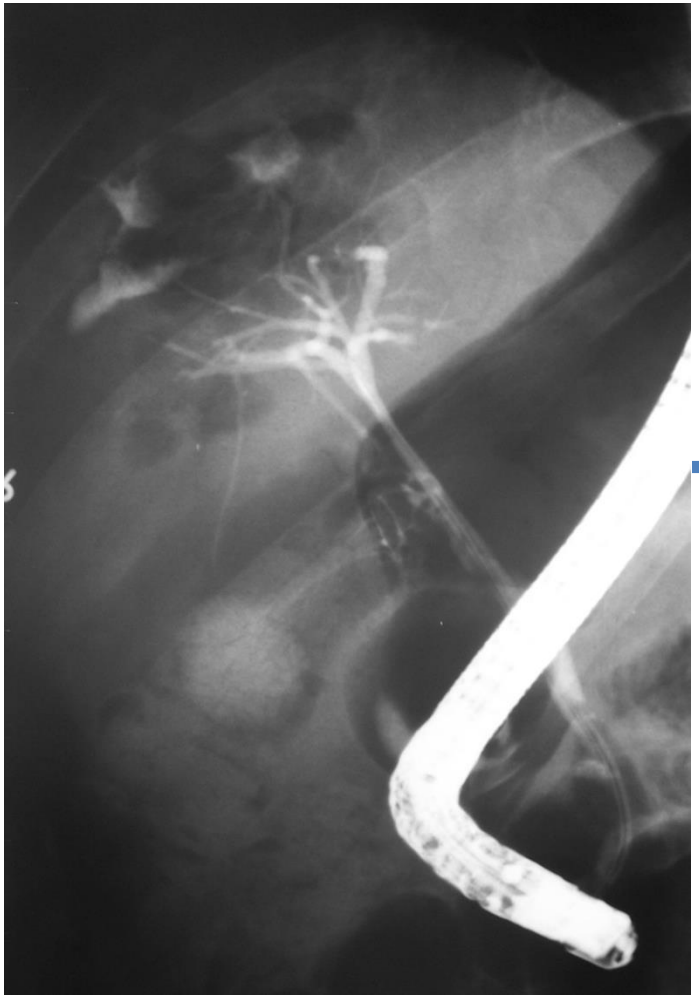

REZEKSİYON KAÇAĞI

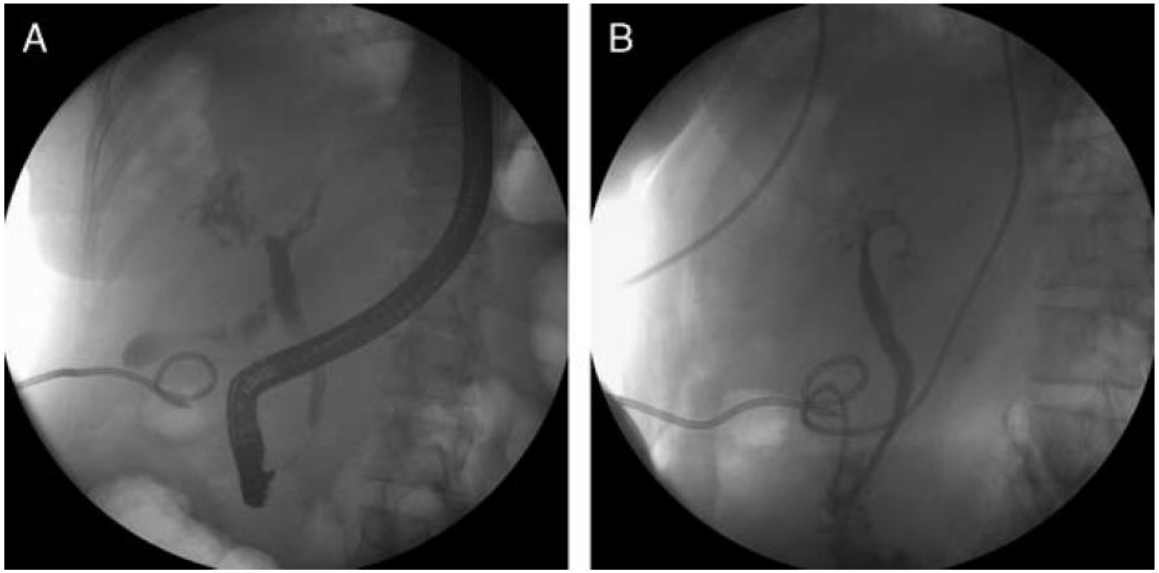

FIGURE 1. A 46-year-old female patient (patient no: 10) with right lobe resection due to rectum carcinoma metastasis. Bile leak can be seen from right hepatic duct stump (A). Bile leak ceased in 7 days by nasobiliary drainage insertion (B).

Surg Laparosc Endosc Percutan Tech 2013;23:453–458

SAFRA YOLU KAÇAKLARI tedavi

Safra yolu 'YARALANMASI'
- Kolesistektomi
- Kist hidatik
- Biliyer rezeksiyon
- Karaciğer transplantasyonu
- ERCP –tip 3- perforasyonu
- Travmatik

Amaç;
1.Bilio-duodenal basınç gradientini azaltmak
2.Kaçağı 'by-pass' etmek
3.Darlık gelişmesini önlemek

Yöntem;
- ES
- MPS
- Fc-SEMS
- ± NBD

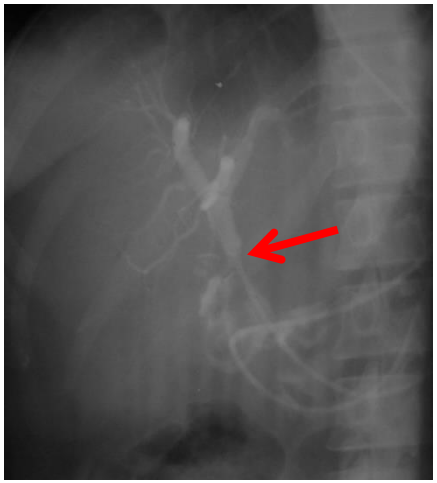

DARLIKSIZ MAJOR YARALANMA MPS

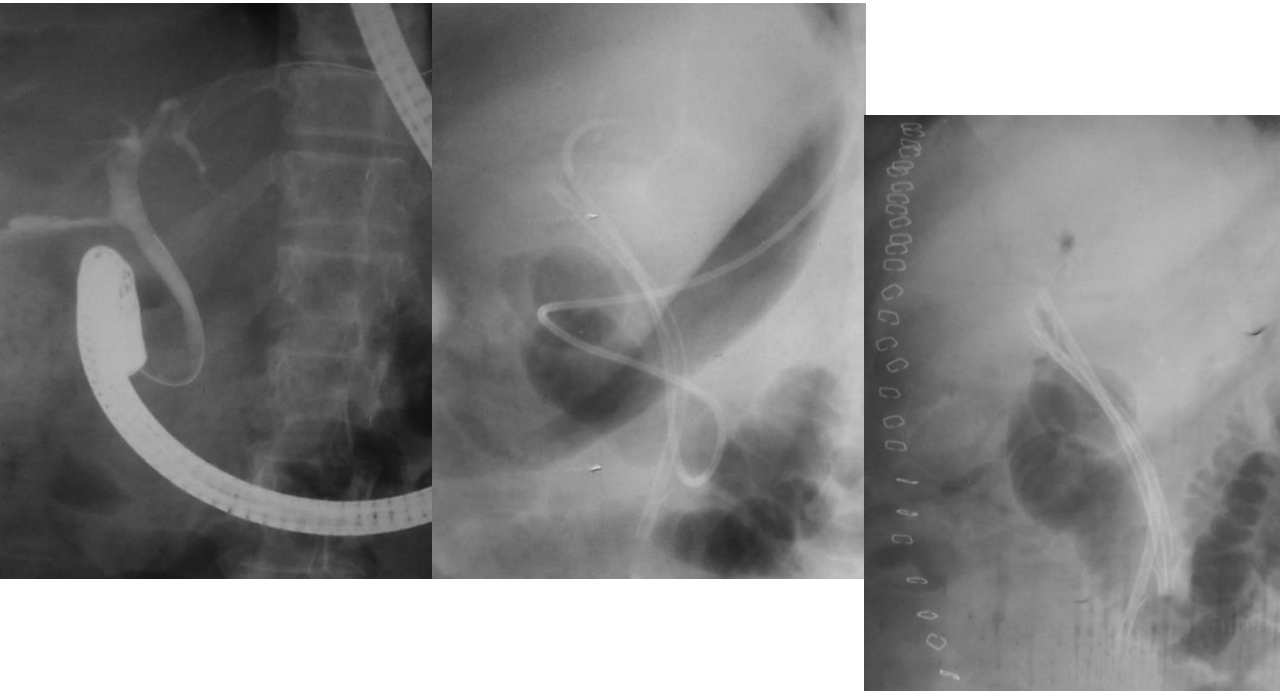

3 ay sonra

DARLIKSIZ MAJOR YARALANMA Fc-SEMS

Aberran kanal yaralanması

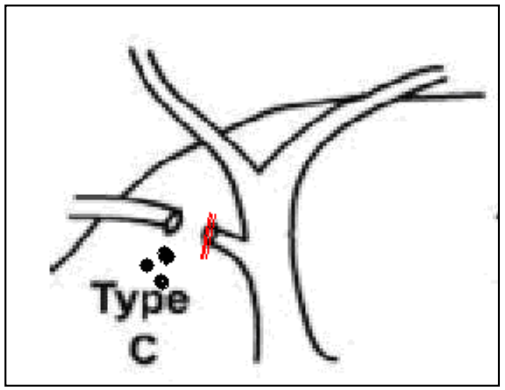

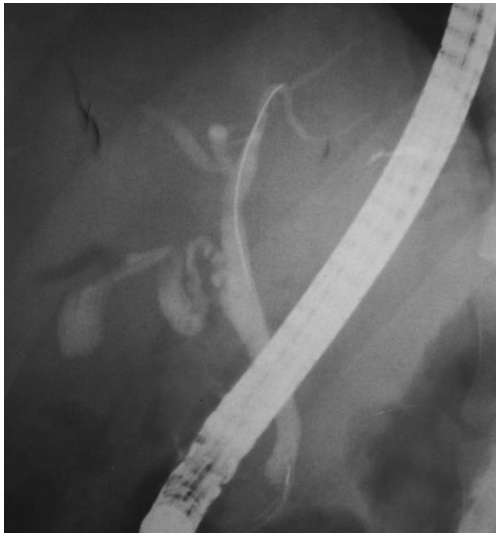

Aberran kanal yaralanması

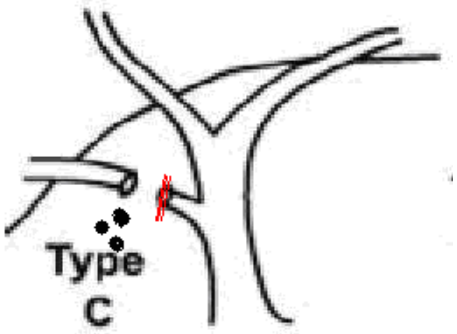

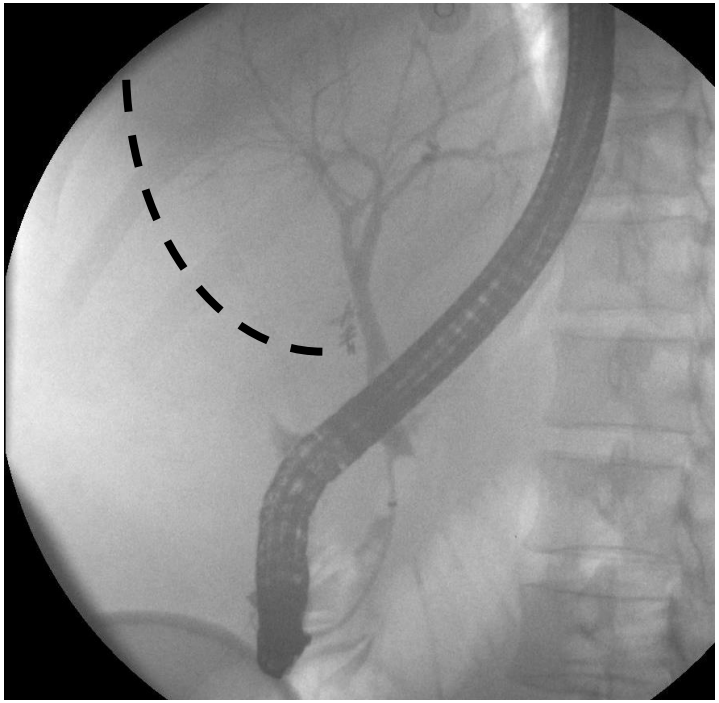

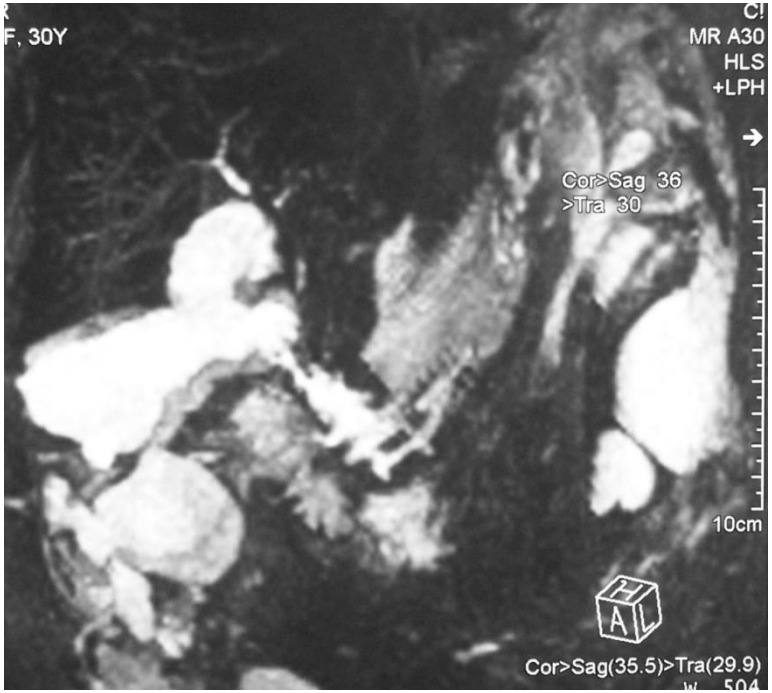

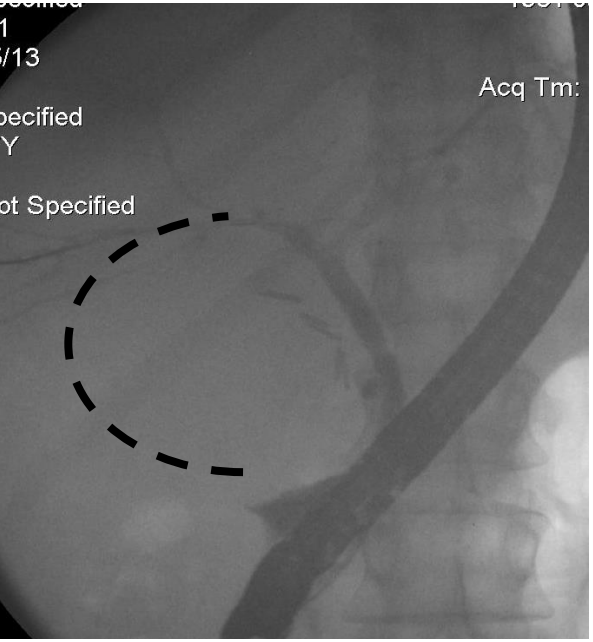
Acq Tm:

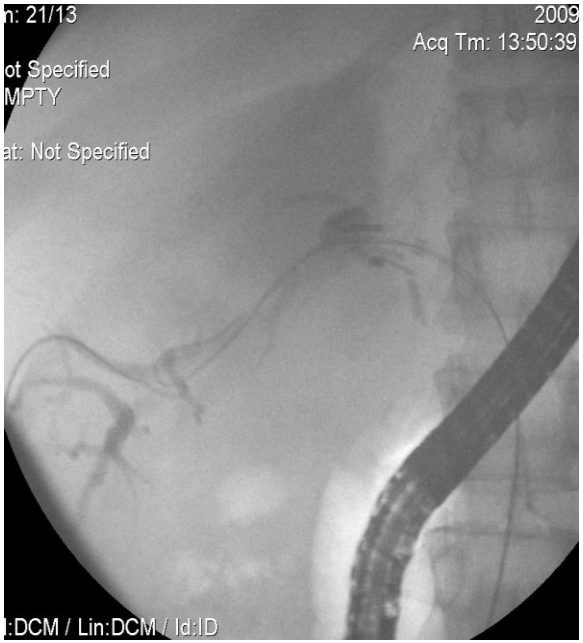
2009
Acq Tm: 13:50:39
:DCM / Lin:DCM / Id:ID

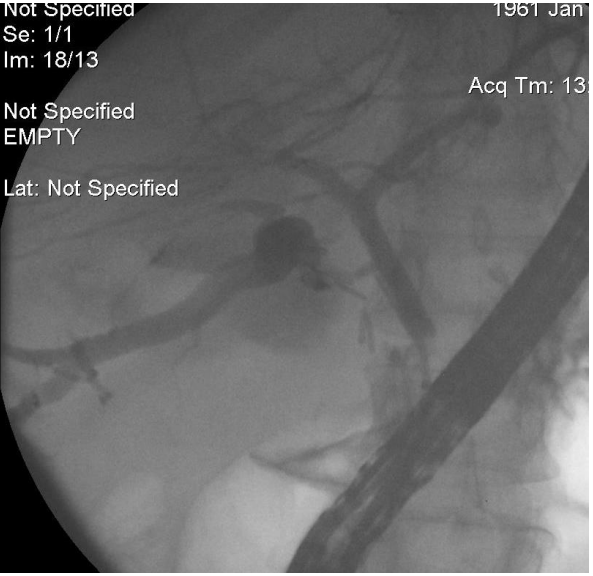
Not Specified
Se: 1/1
Im: 18/13
Not Specified
EMPTY
Lat: Not Specified

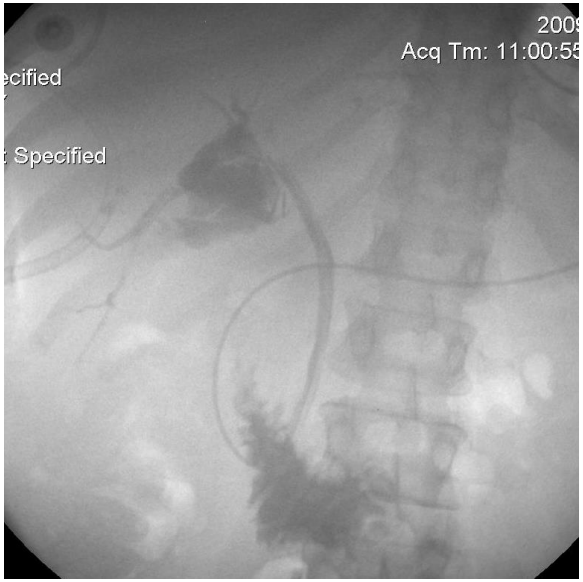
Acq Tm: 11:00:55

OLT MPS

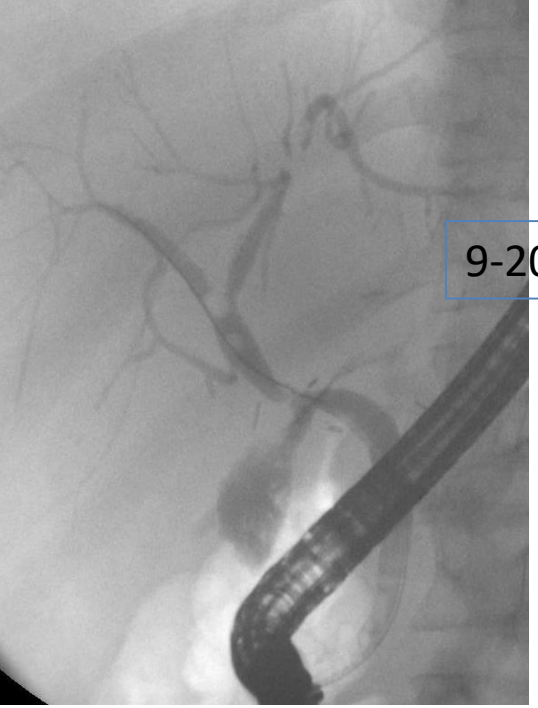

9-2010

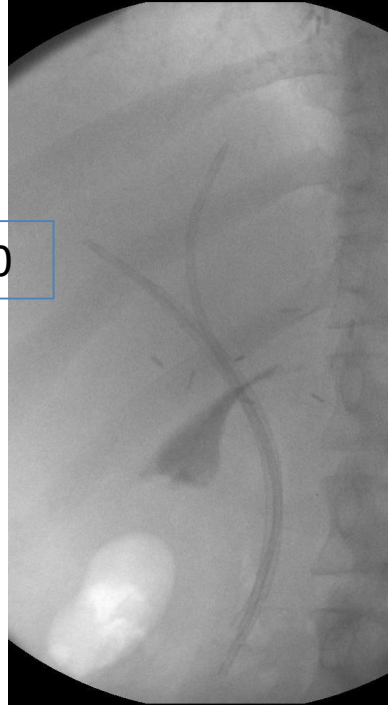

12-2010

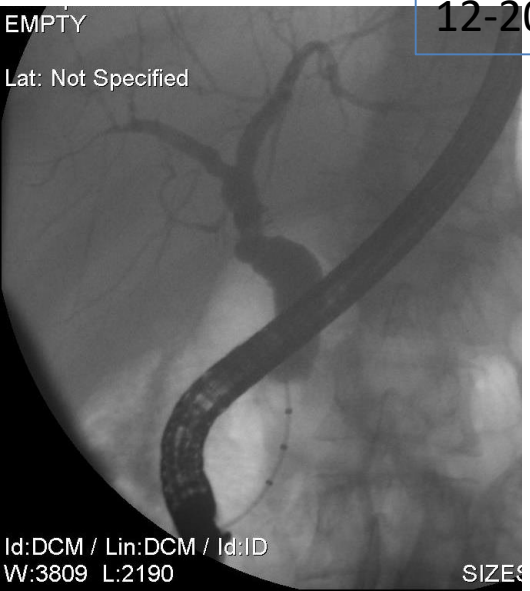

3-2011

DONÖR REZEKSİYON KAÇAĞI MPS

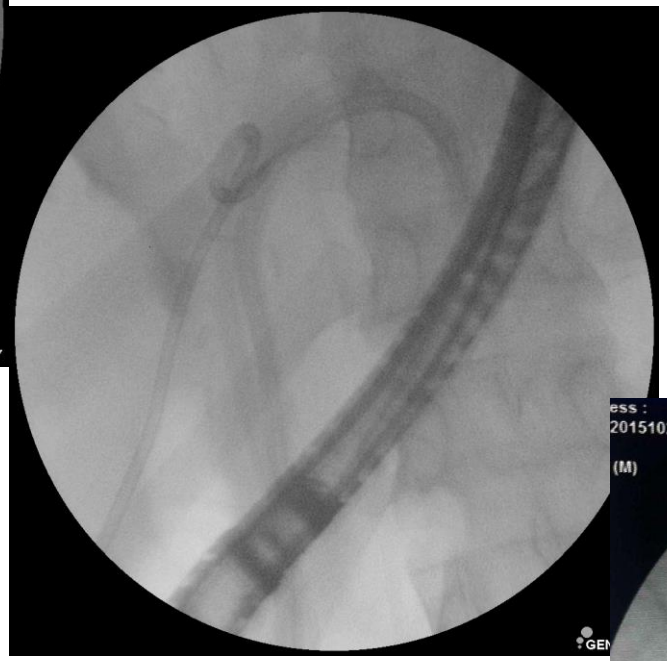

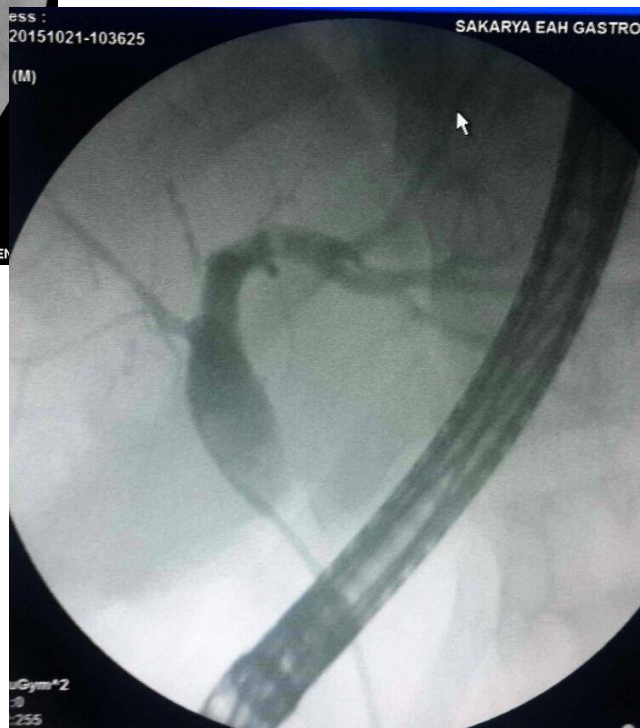

ERCP ENDİKASYONLARI

Biliyer

...Safra yolu taşları
...Safra kaçakları
...Safra yolu benign darlıkları
...Safra yolu malign darlıkları
...Diğer endikasyonlar (konjenital hastalıklar vb)

Pankreatik

...

SAFRA YOLU BENİGN DARLIKLARI etyoloji

Postoperatif

Kolesistektomi
Karaciğer transplantasyonu
Karaciğer rezeksiyonu
Biliyer anastomozlar
Biliary rekonstrüksiyon
Biliyer-enterik anastomozlar

İnflamatuvar

Kronik ve Akut pankreatit
Primer sklerozan kolanjit
Otoimmun pankreatit
IgG4 kolanjiopati
Enfeksiyonlar (rekürren bakteriyel kolanjit, tbc)
Radyoterapi

Diğerleri

İskemik (Portal biliopati, hepatik arter trombozu, Tx-non-anastomotik striktür)
Travma
Mirizzi sendromu

SAFRA YOLU BENİGN DARLIKLARI etyoloji

Postoperatif

Kolesistektomi
Karaciğer transplantasyonu
Karaciğer rezeksiyonu
Biliyer anastomozlar
Biliary rekonstrüksiyon
Biliyer-enterik anastomozlar

Amaç;

- Safra yollarında 'remodeling'
- Stentsiz yaşam

Yöntem;

- MPS
- Fc-SEMS

İnflamatuvar

Kronik ve Akut pankreatit
Primer sklerozan kolanjit
Otoimmun pankreatit
IgG4 kolanjiopati
Enfeksiyonlar (rekürren bakteriyel kolanjit, tbc)
Radyoterapi

Diğerleri

İskemik (Portal biliopati, hepatik arter trombozu, Tx-non-anastomotik striktür)
Travma
Mirizzi sendromu

KOLESİSTEKTOMİ YARALANMASI MPS

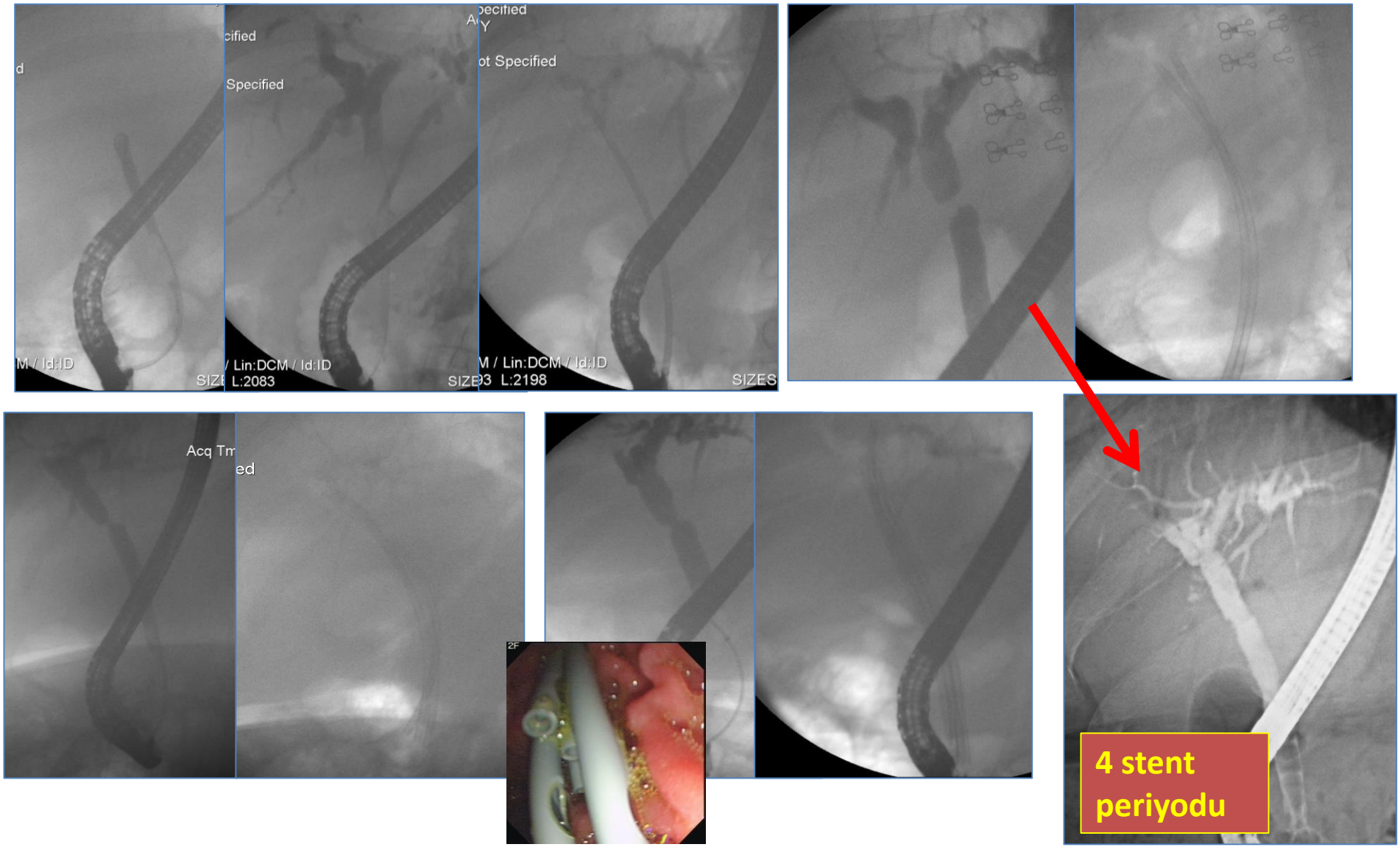

KOLESİSTEKTOMİ YARALANMASI Fc-SEMS

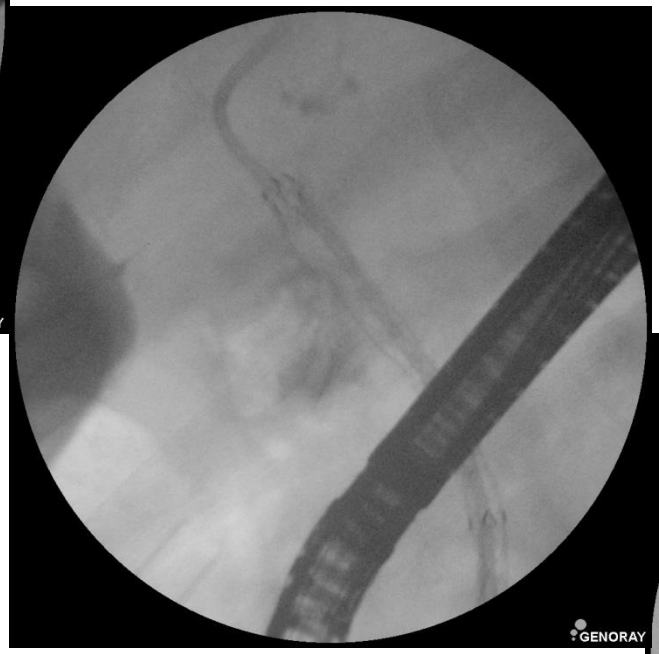



OLT MPS

EB, K, 68, HCV, OLT

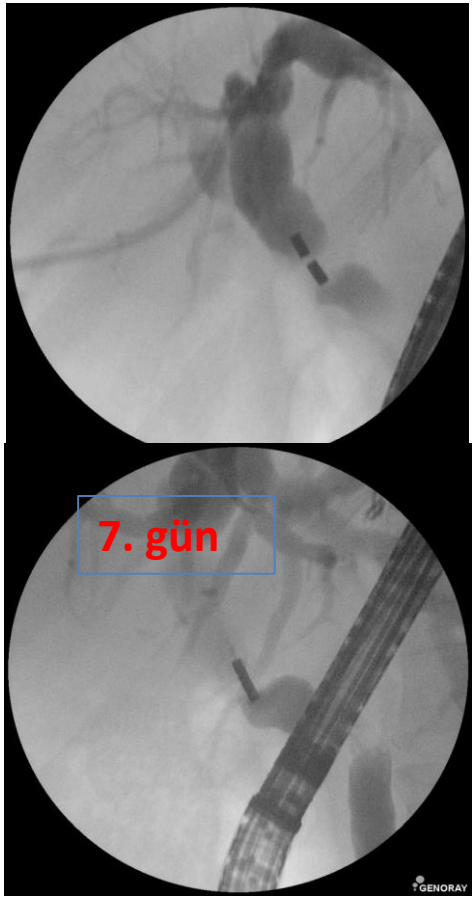

LRLT MPS

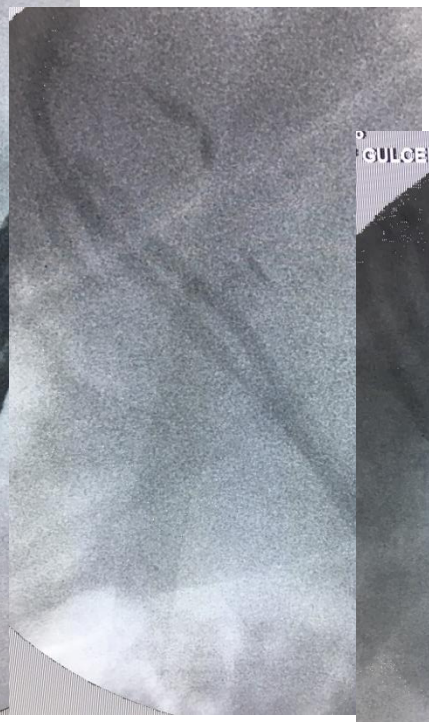

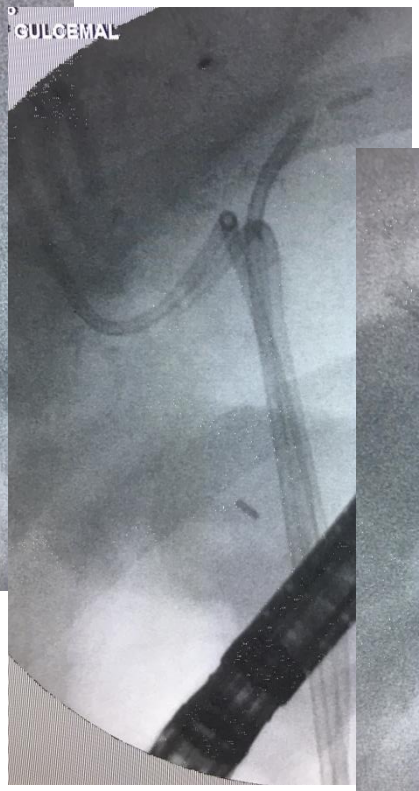

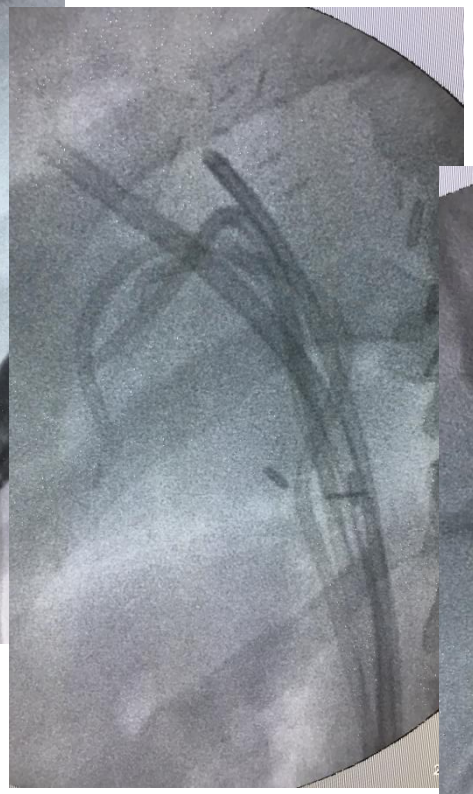

OLT Fc-SEMS

KHD, E, 42, etilik S, OLT,

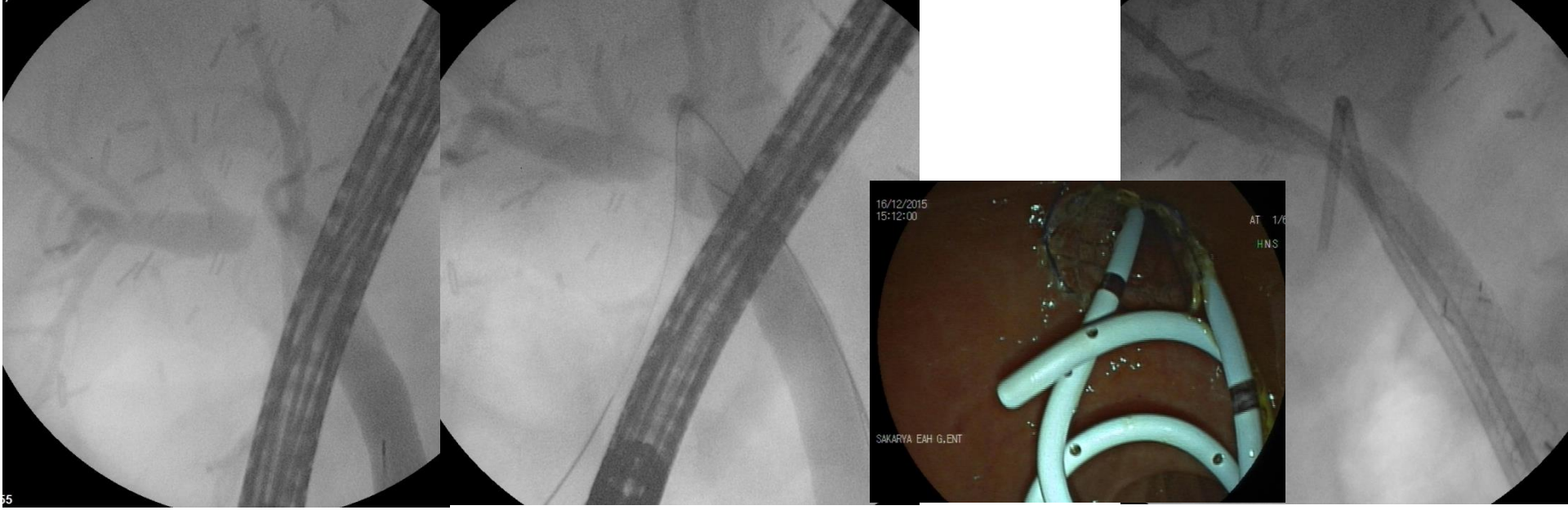

16.12.2015

KS, 61, K
OİH,
37 ay,
LDLT
3 ERCP

16.02.2016

LRLT
Fc-SEMS

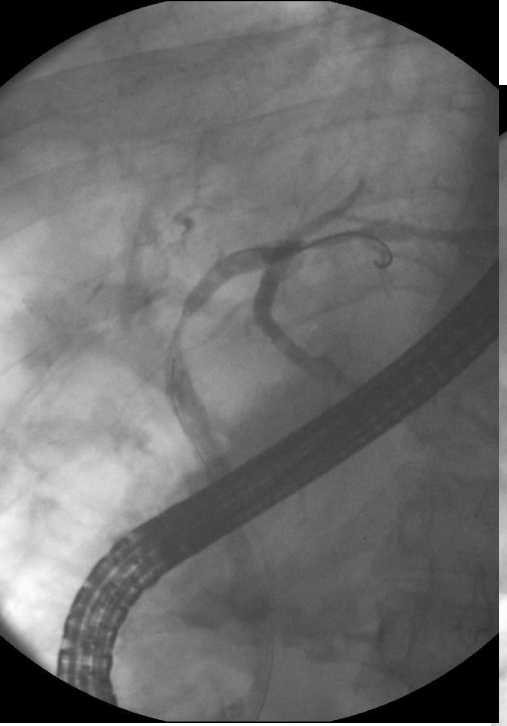

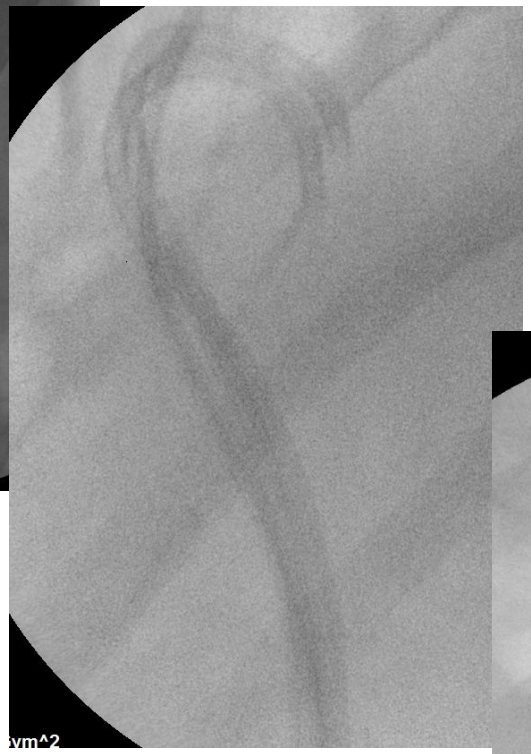

REZEKSİYON DARLIĞI MPS DONOR

ROUX-Y-HEPATİKOJEJUNOSTOMİ MPS

41, K, LK yaralanması

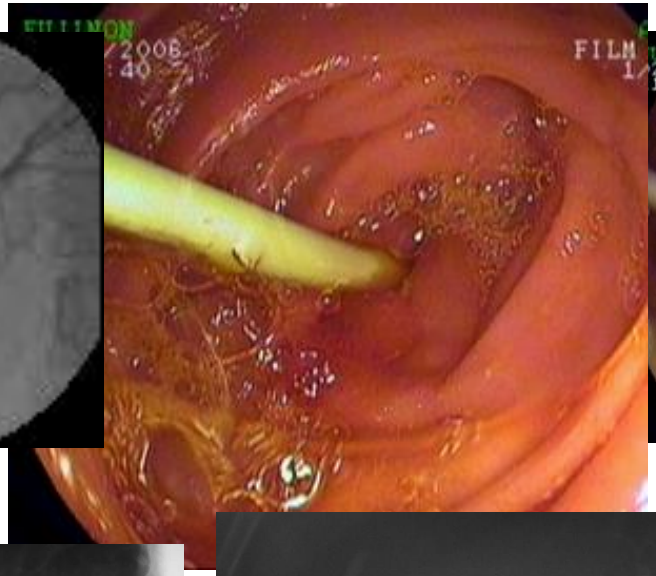

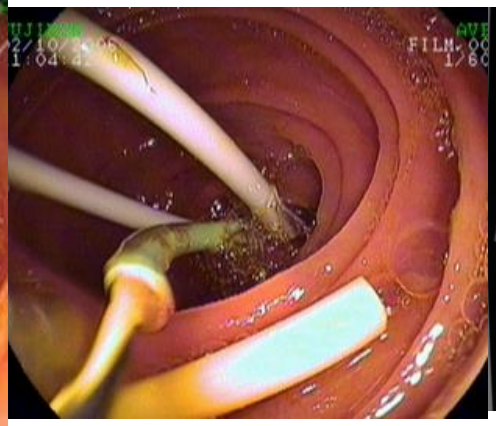

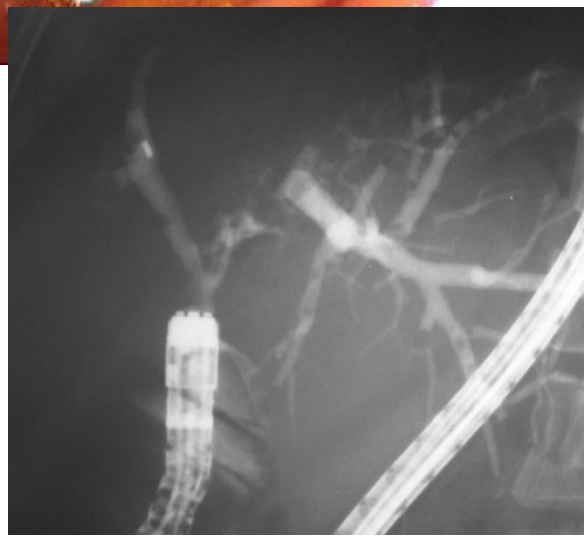

4 ay sonra

SAFRA YOLU BENİGN DARLIKLARI etyoloji

Postoperatif

Kolesistektomi
Karaciğer transplantasyonu
Karaciğer rezeksiyonu
Biliyer anastomozlar
Biliary rekonstrüksiyon
Biliyer-enterik anastomozlar

İnflamatuvar

Kronik ve Akut pankreatit
Primer sklerozan kolanjit
Otoimmun pankreatit
IgG4 kolanjiopati
Enfeksiyonlar (rekürren bakteriyel kolanjit, tbc)
Radyoterapi

Diğerleri

İskemik (Portal biliopati, hepatik arter trombozu, Tx-non-anastomotik striktür)
Travma
Mirizzi sendromu

Amaç; etyolojiye göre değişken

- Stentsiz yaşam
(KP)
- Semptomatik tedavi
(PSC, radyoterapi)
- Köprü tedavi
(AP, OİP, IgG4 kolanjiopati, PSC)

Yöntem;

- MPS, Fc-SEMS
- Dilatasyon ve/veya plastik stent
- İlaç tedavisi

KRONİK PANKREATİT

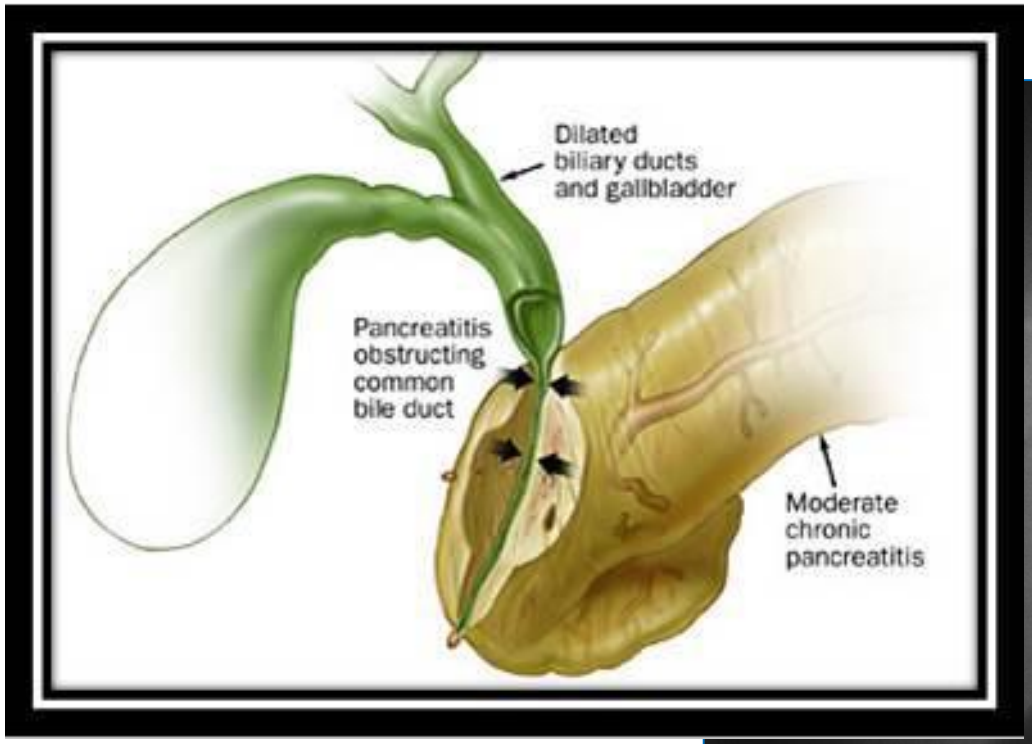

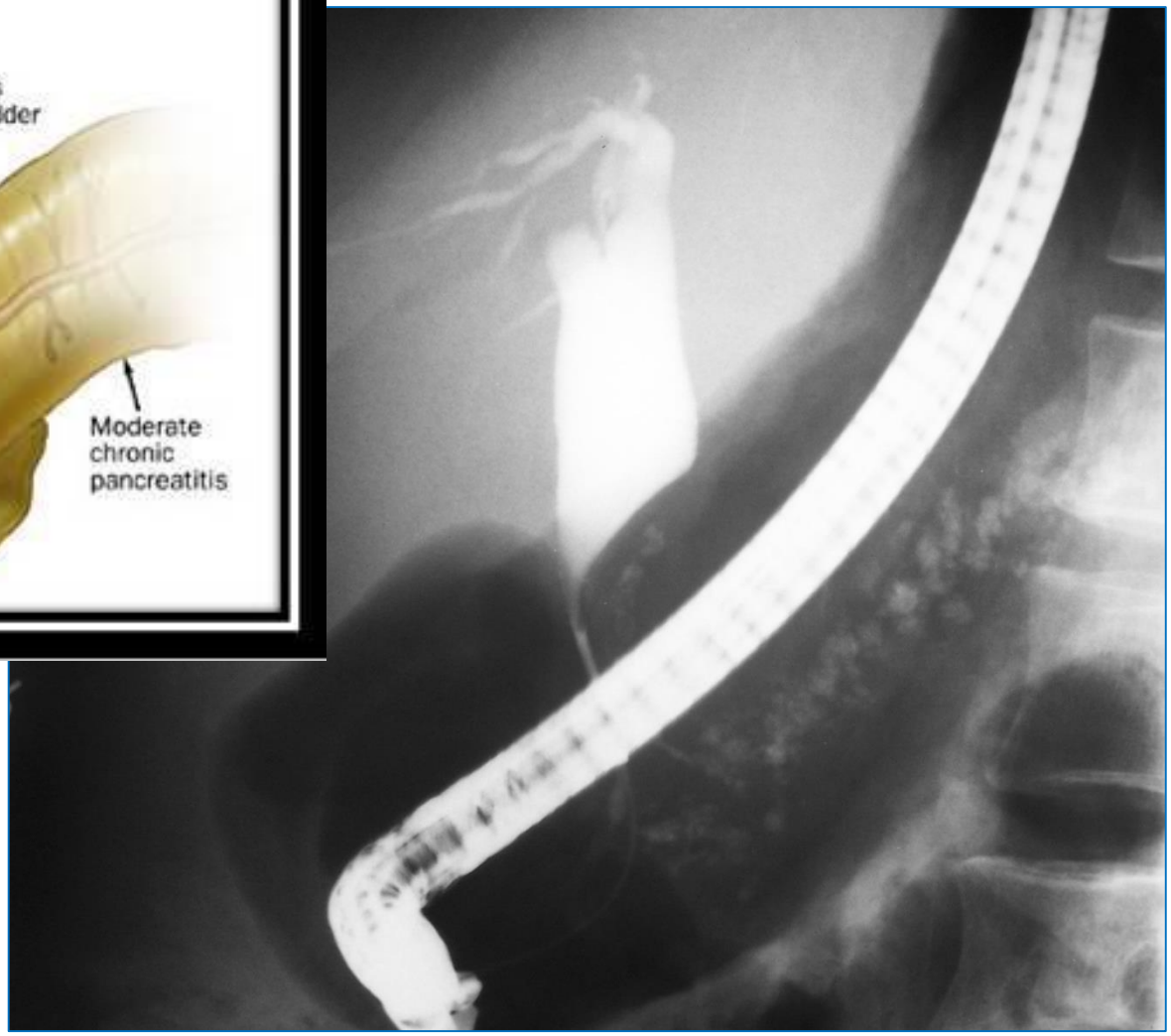

KRONİK PANKREATİT MPS

KRONİK PANKREATİT FC-SEMS

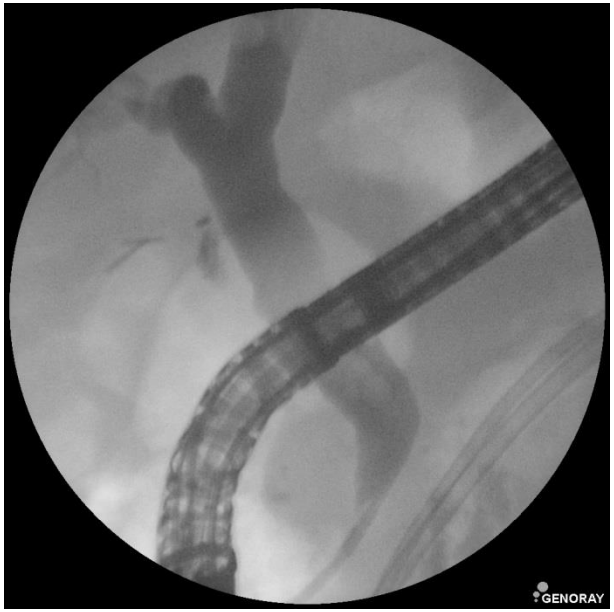

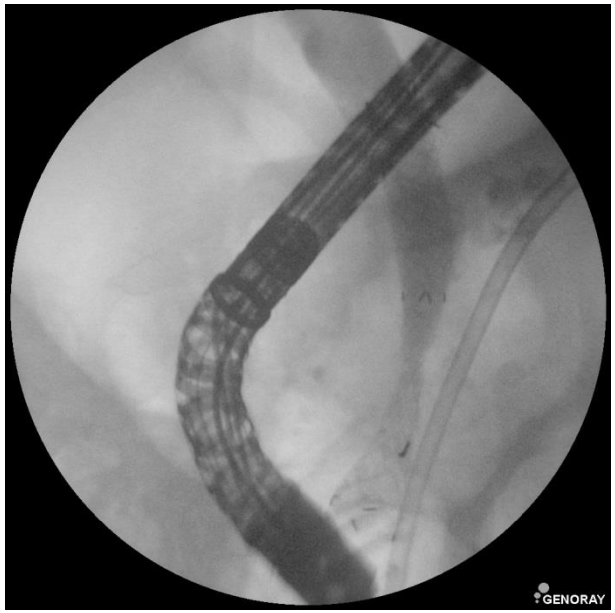

AKUT PANKREATİT PS

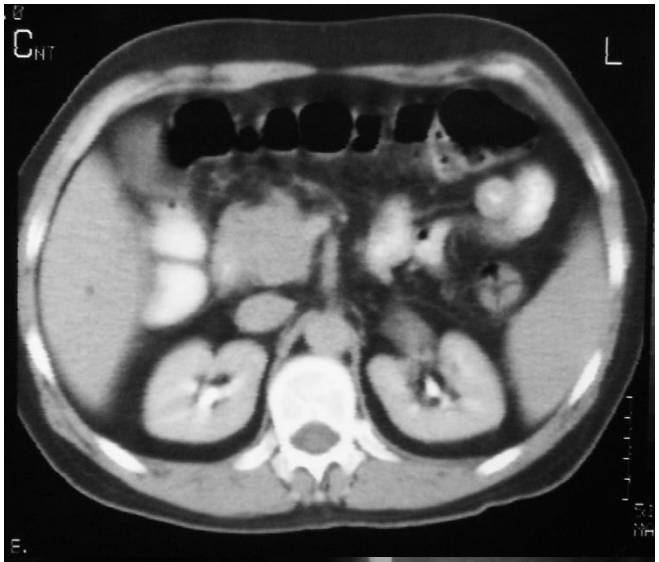

4 ay

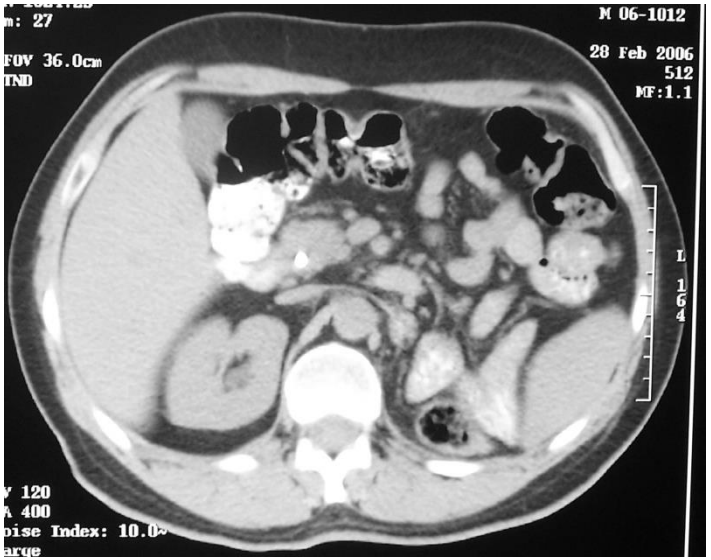

PSC dilatasyon

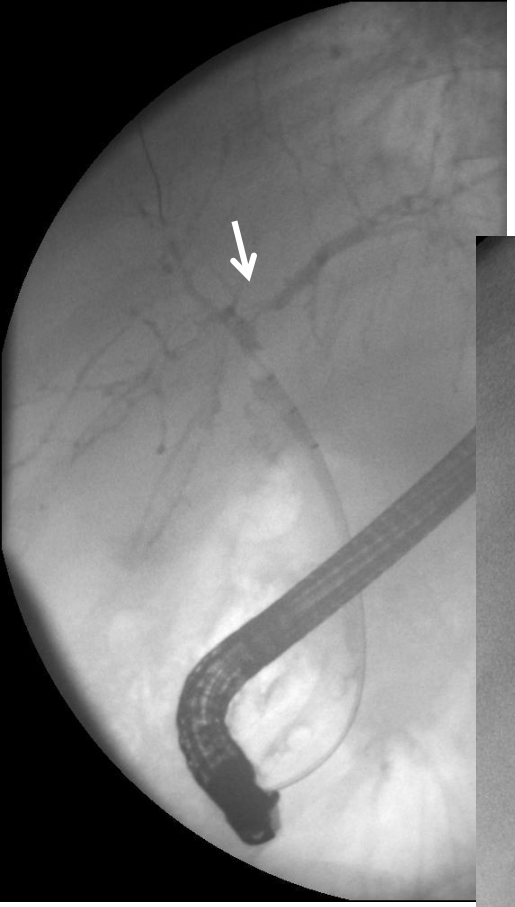

PSC dilatasyon ve stent

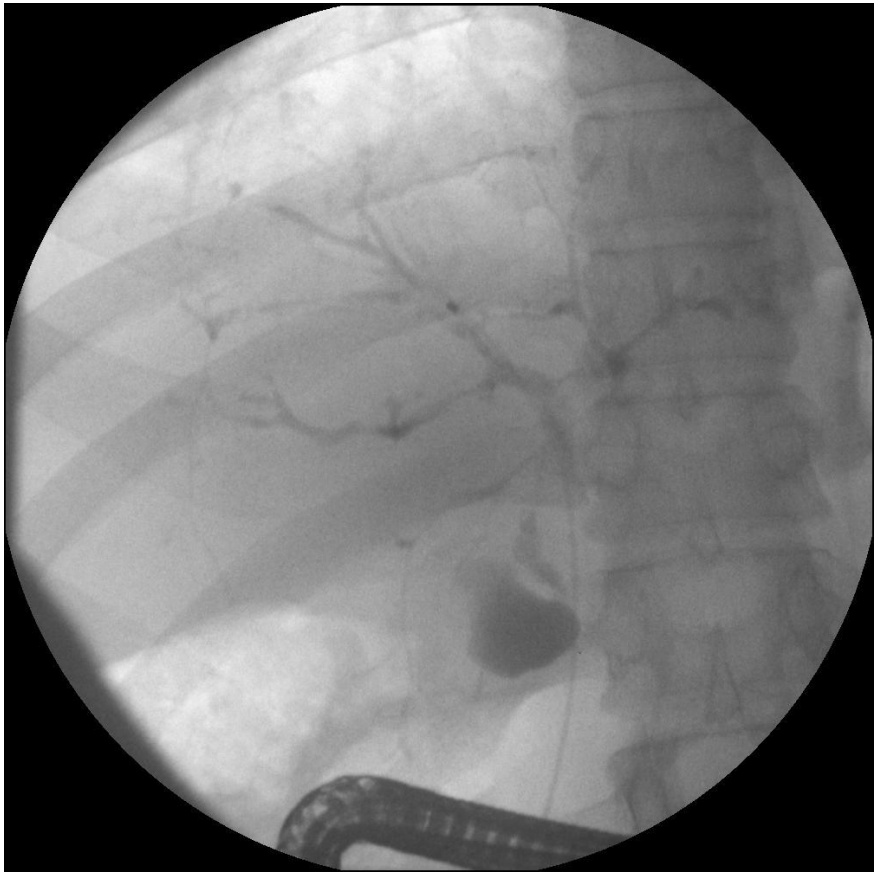

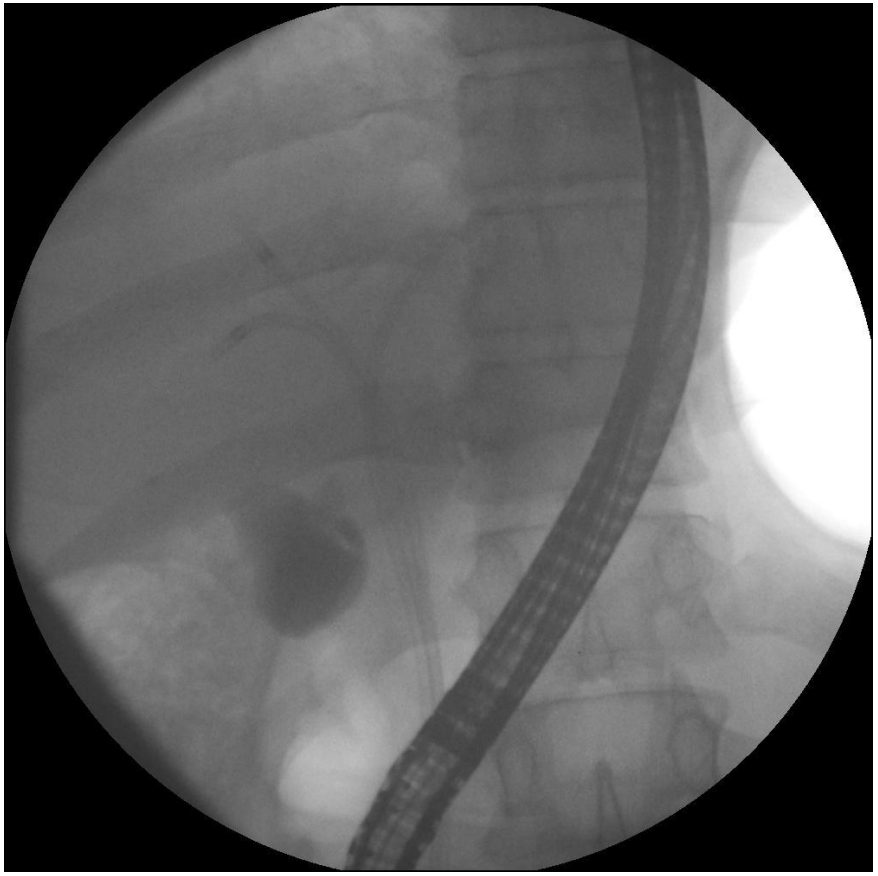

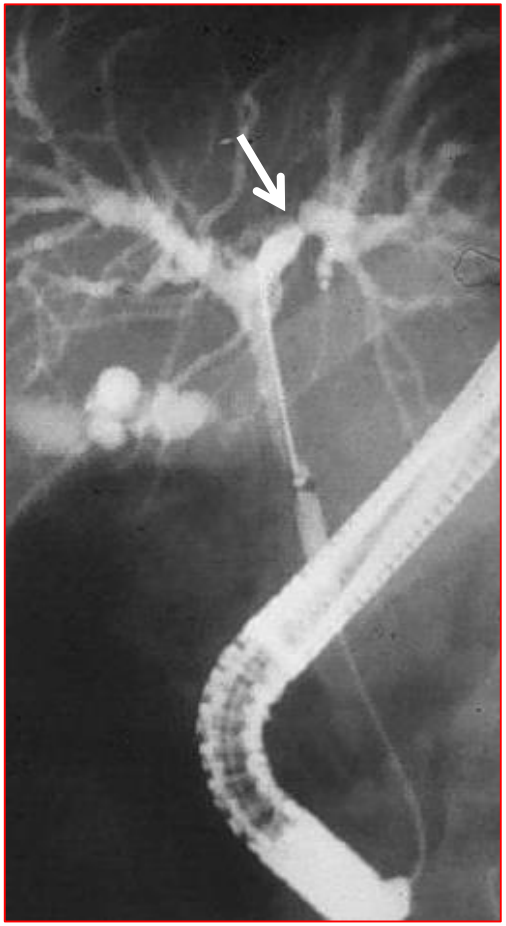

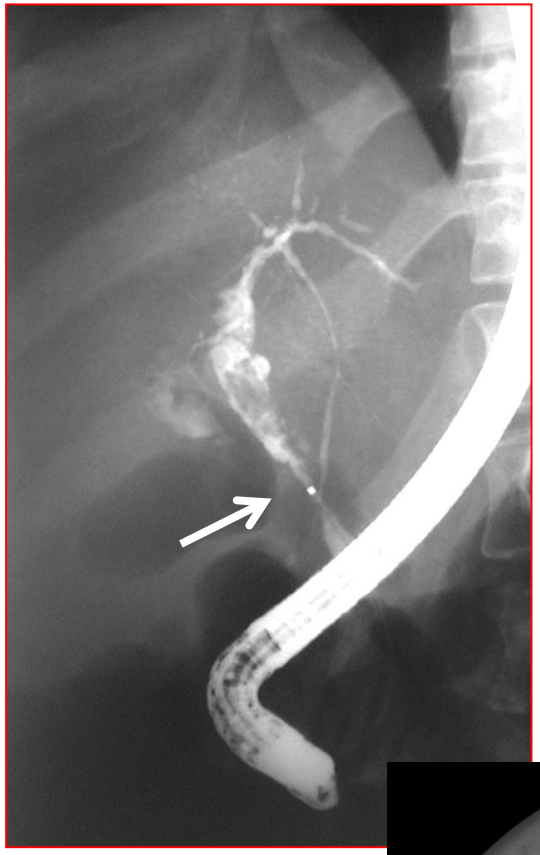

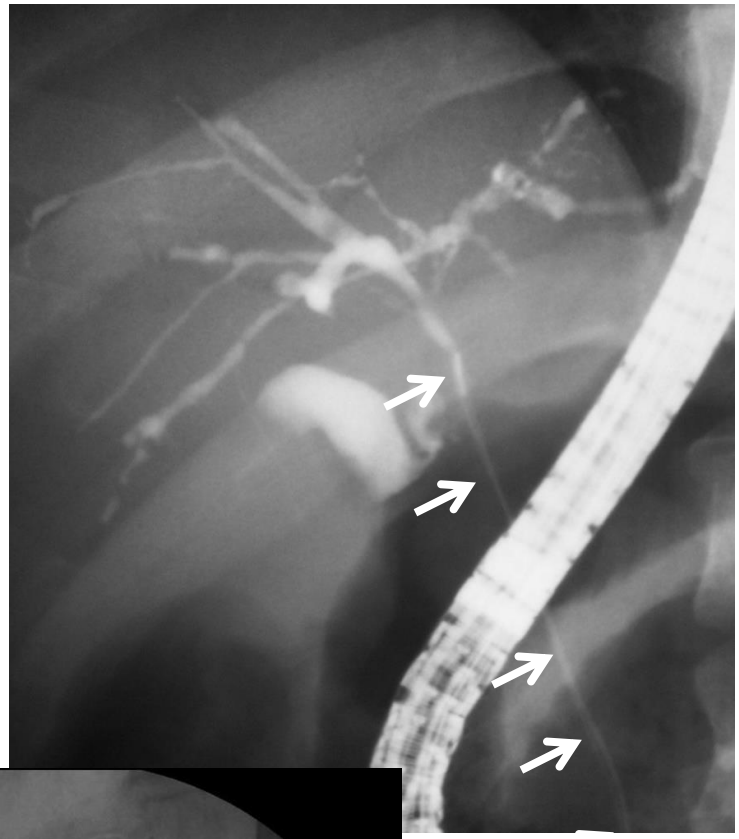

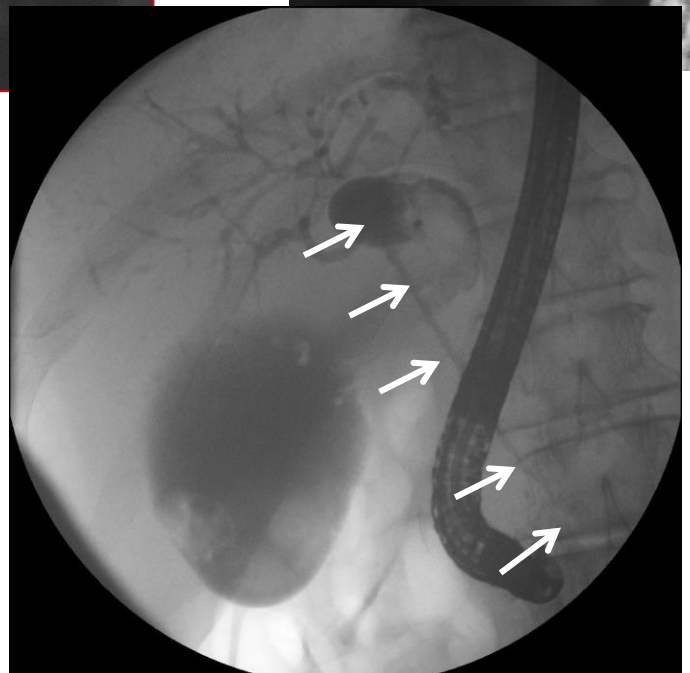

PSC DOMİNANT DARLIK

Kısa segment

Uzun segment

Diffüz

OTOİMMUN PANKREATİT stent

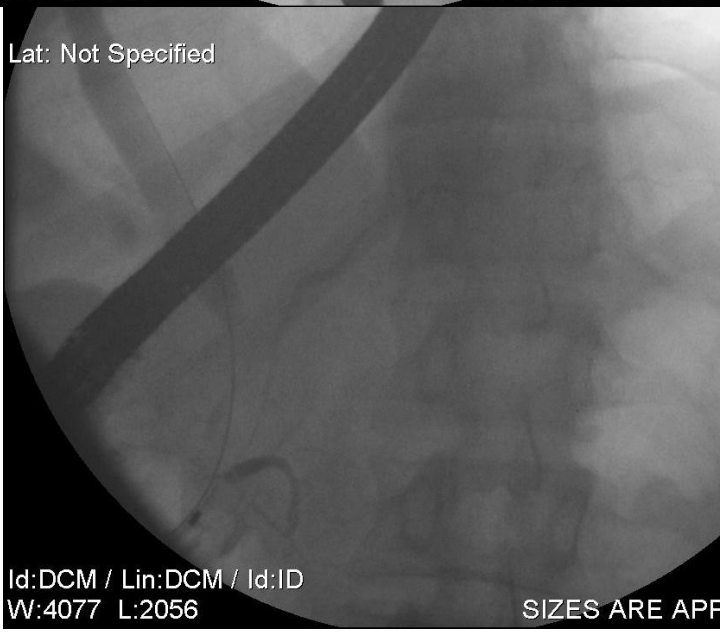

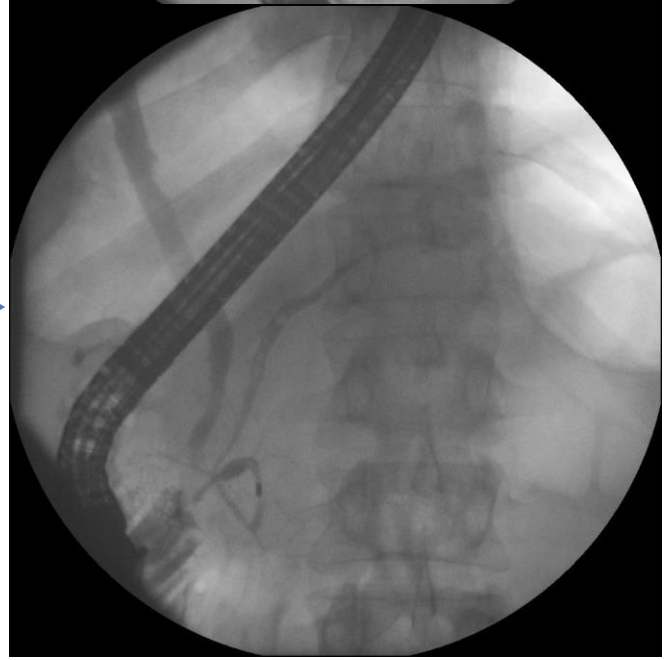

RADYOTERAPİ PS

SAFRA YOLU BENİGN DARLIKLARI etyoloji

Postoperatif

Kolesistektomi
Karaciğer transplantasyonu
Karaciğer rezeksiyonu
Biliyer anastomozlar
Biliary rekonstrüksiyon
Biliyer-enterik anastomozlar

İnflamatuvar

Kronik ve Akut pankreatit
Primer sklerozan kolanjit
Otoimmun pankreatit
IgG4 kolanjiopati
Enfeksiyonlar (rekürren bakteriyel kolanjit, tbc)
Radyoterapi

Diğerleri

İskemik (Portal biliopati, hepatik arter trombozu, Tx-non-anastomotik striktür)
Travma
Mirizzi sendromu

Amaç; etyolojiye göre değişken

- Stentsiz yaşam (travma)
- Semptomatik tedavi (İskemik, portal biliopati)
- Köprü tedavi (Mirizzi)

Yöntem;

- MPS, Fc-SEMS
- Dilatasyon ve/veya plastik stent

PORTAL BİLİOPATİ

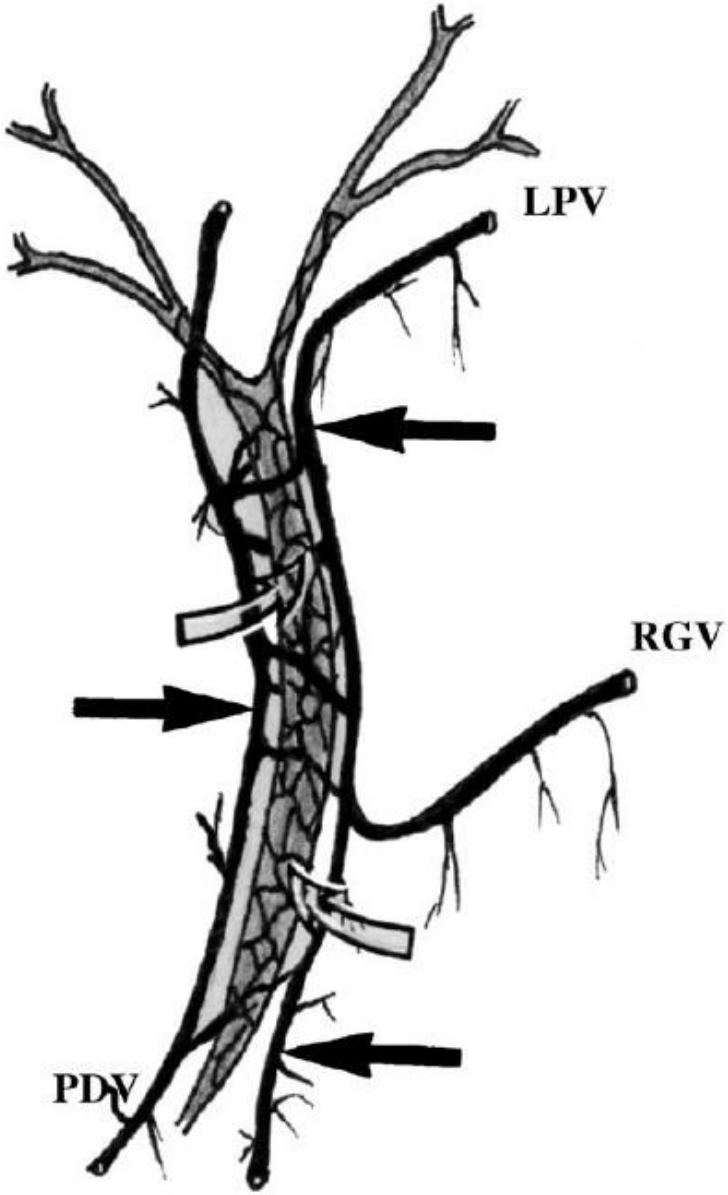

Fig. 1. Line drawing of the paracholedochal venous plexus of Petren [9] (black arrows) and the epicholedochal venous plexus of Saint [10] (open arrows). LPV=left portal vein, PDV=pancreaticoduodenal vein, RGV=right gastric vein.

SUPERİOR MEZENTERİK ARTER YOLUYLA ANJİOGRAFİ

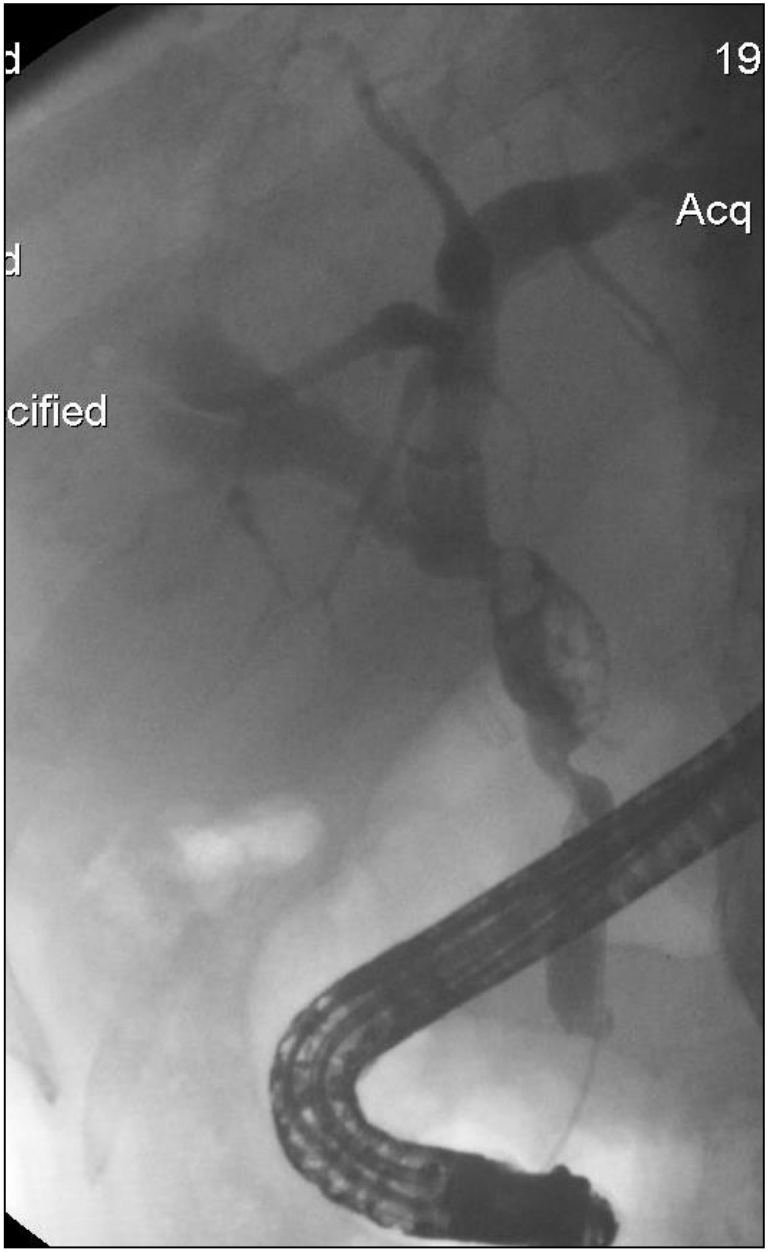

PORTAL BİLİOPATİ

PORTAL BİLİOPATİ

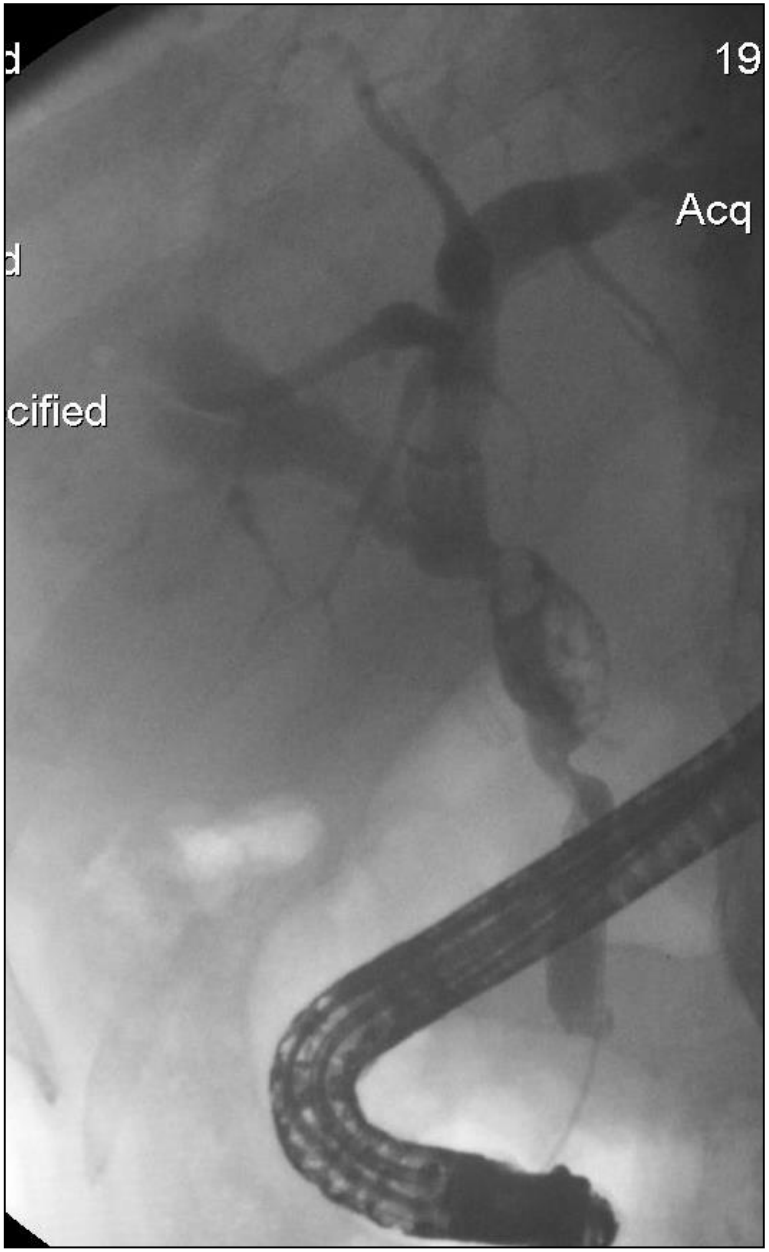

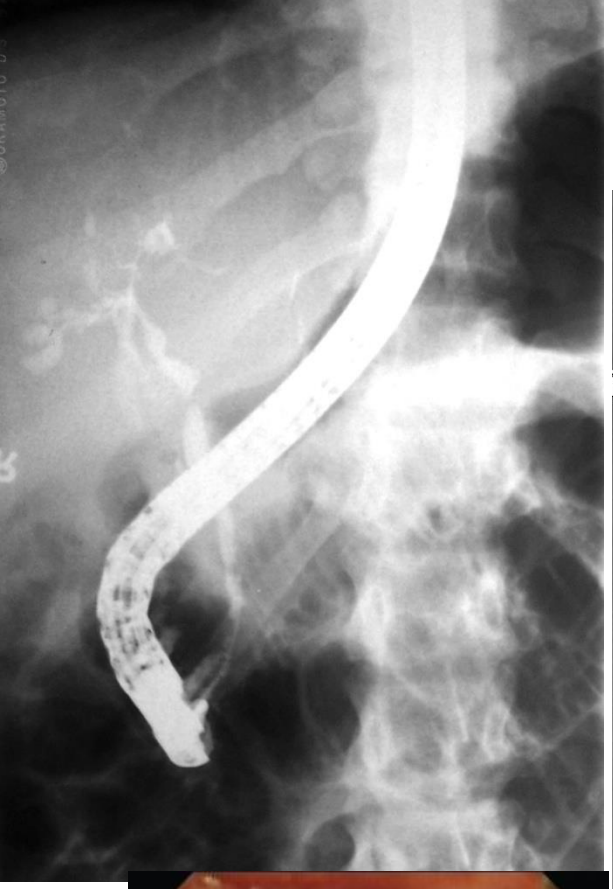

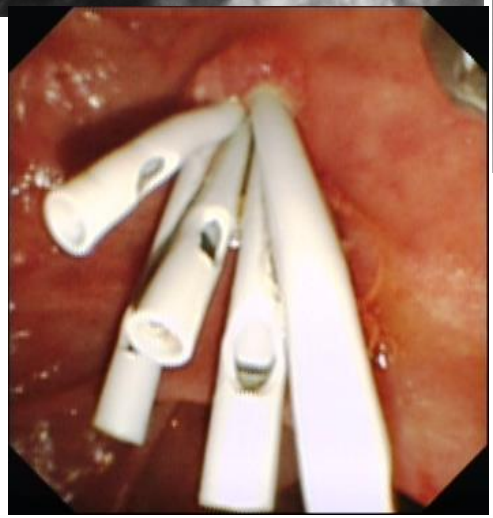

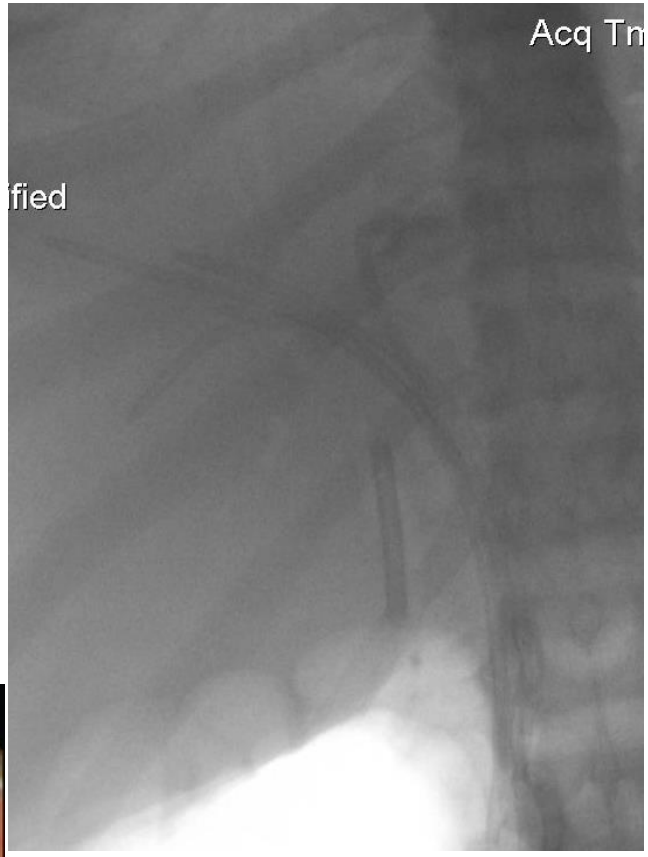

NAS

NAS

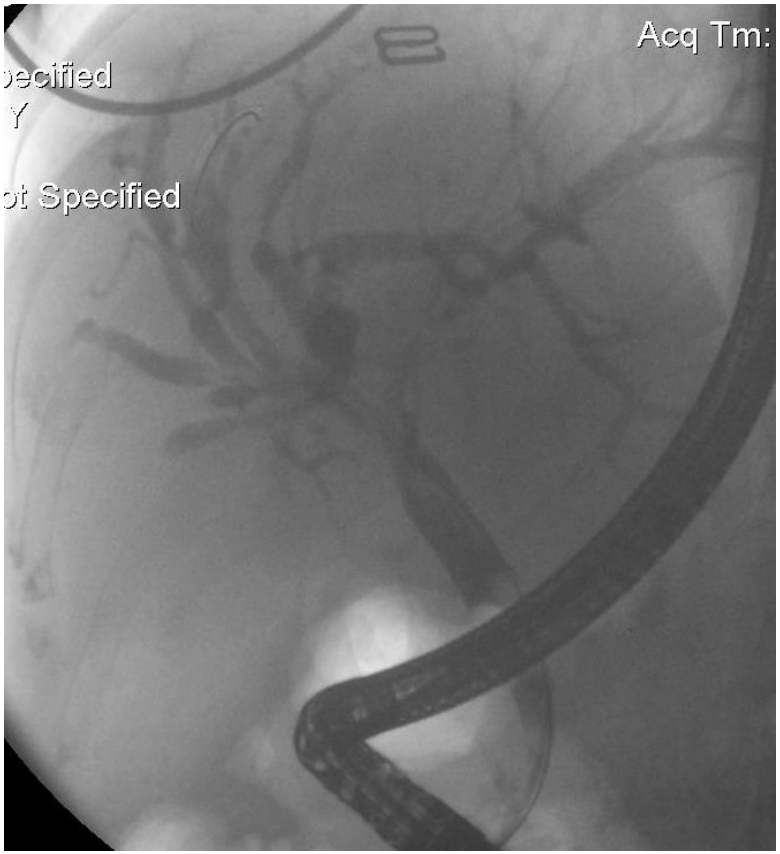

2007

2010

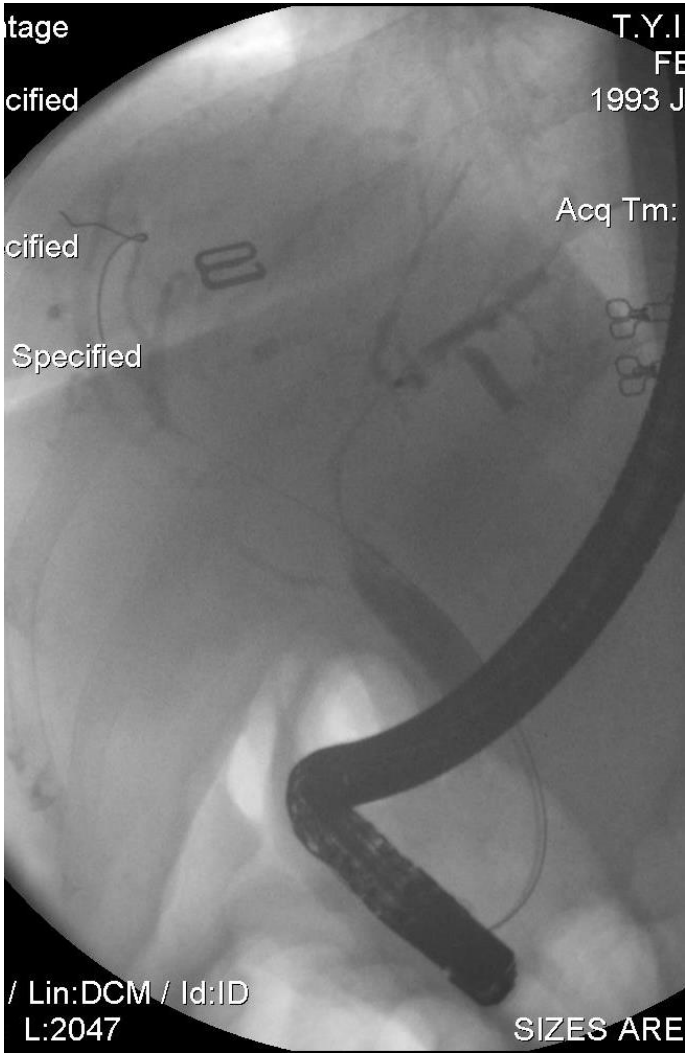

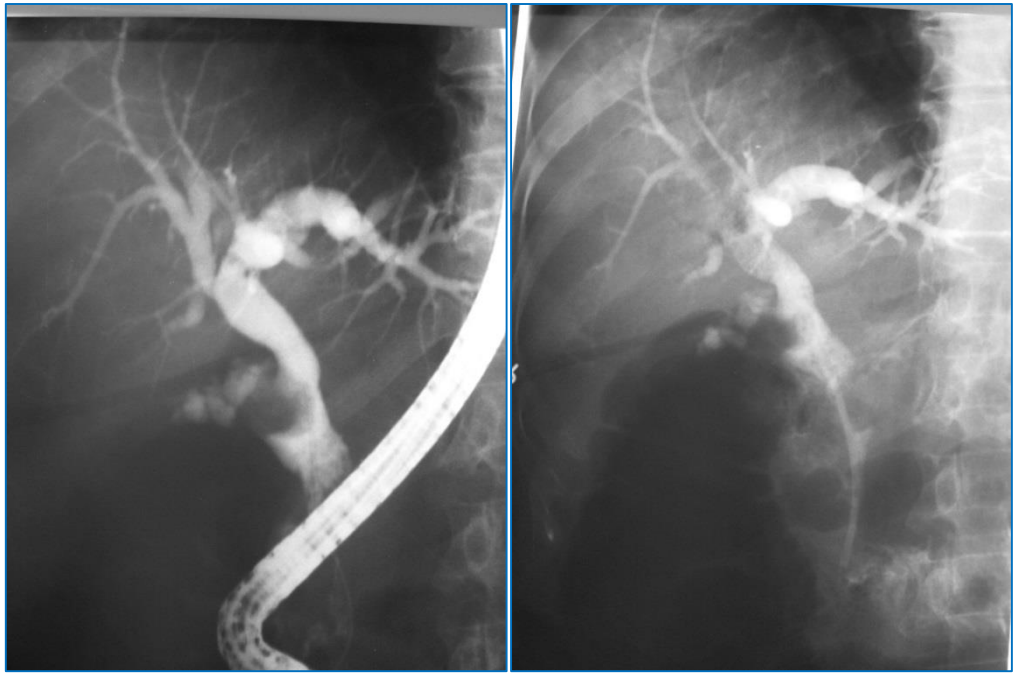

MİRİZZİ

ERCP ENDİKASYONLARI

Biliyer

...Safra yolu taşları
...Safra kaçakları
...Safra yolu benign darlıkları
...Safra yolu malign darlıkları
...Diğer endikasyonlar (konjenital hastalıklar vb)

Pankreatik

...

MALİGN BİLİYER DARLIKLAR

- DİSTAL

---Pankreas başı Ca

---Distal kolanjio Ca

---Oddi tümörü

---Duodenum tümörü

---Metastazlar

---Safra kesesi kanseri

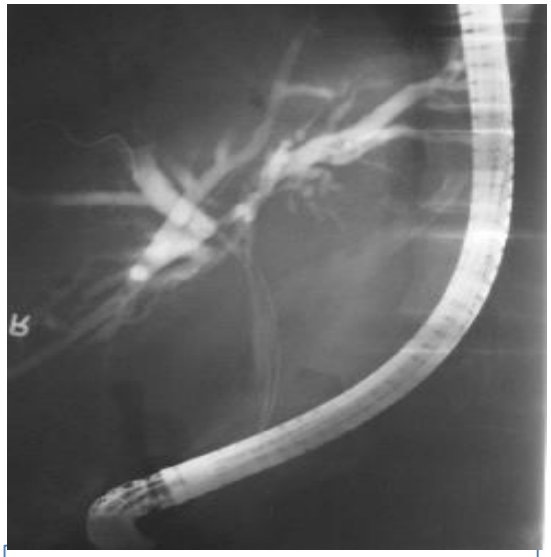

- HİLER

---Klatskin tümörü

---HCC

---Metastazlar

---Safra kesesi kanseri

MALİGN BİLİYER DARLIKLAR

	Distal darlık	Hiler darlık
Preoperatif drenaj		
Unrezektabl hasta		
	DİSTAL …Karaciğer rezeksiyonu gerekmez …Hedef bilirubin <15 mg /dl	HİLER …Karaciğer rezeksiyonu gerekir …Hedef bilirubin normale yakın

MALİGN BİLİYER DARLIKLAR

	Distal darlık	Hiler darlık
Preoperatif drenaj	Plastik stent (10F) Tam kaplı metal stent Kısa kapsız/parsiyel kaplı stent	
Unrezektabl hasta		

GENORAY

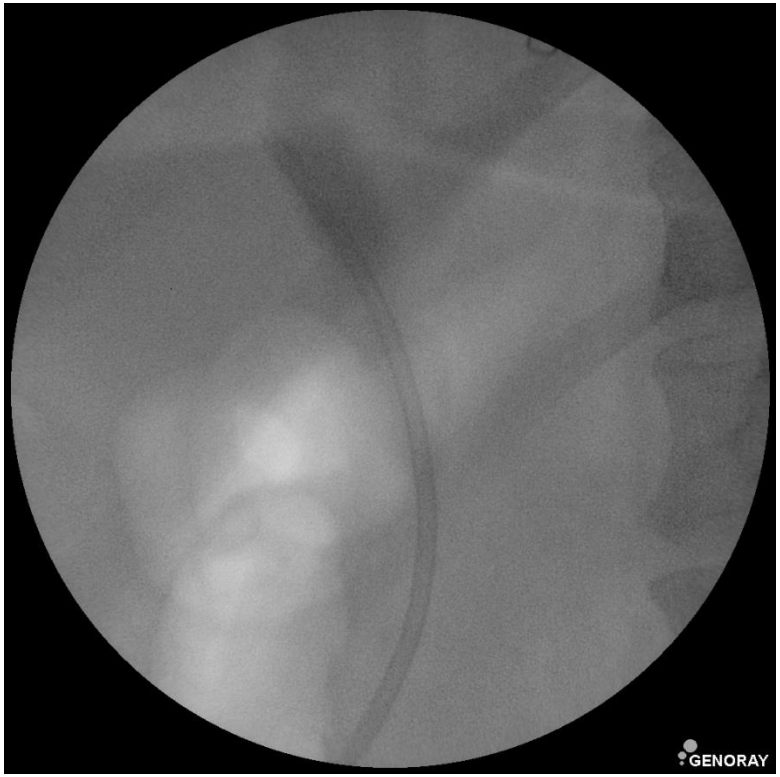
GENORAY

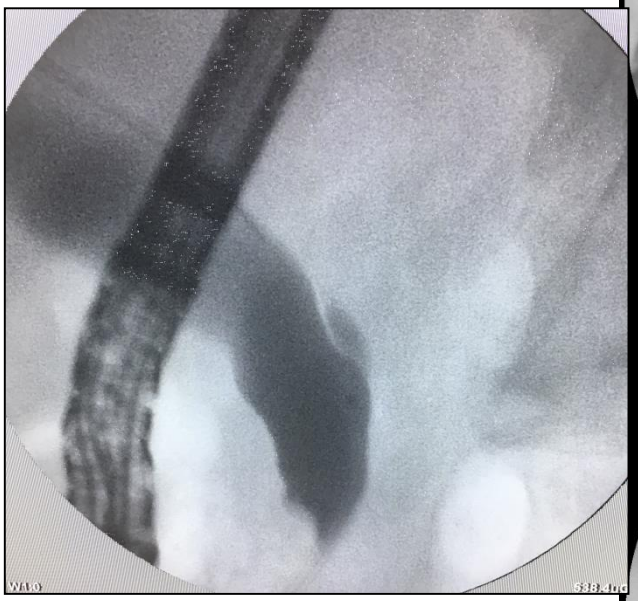

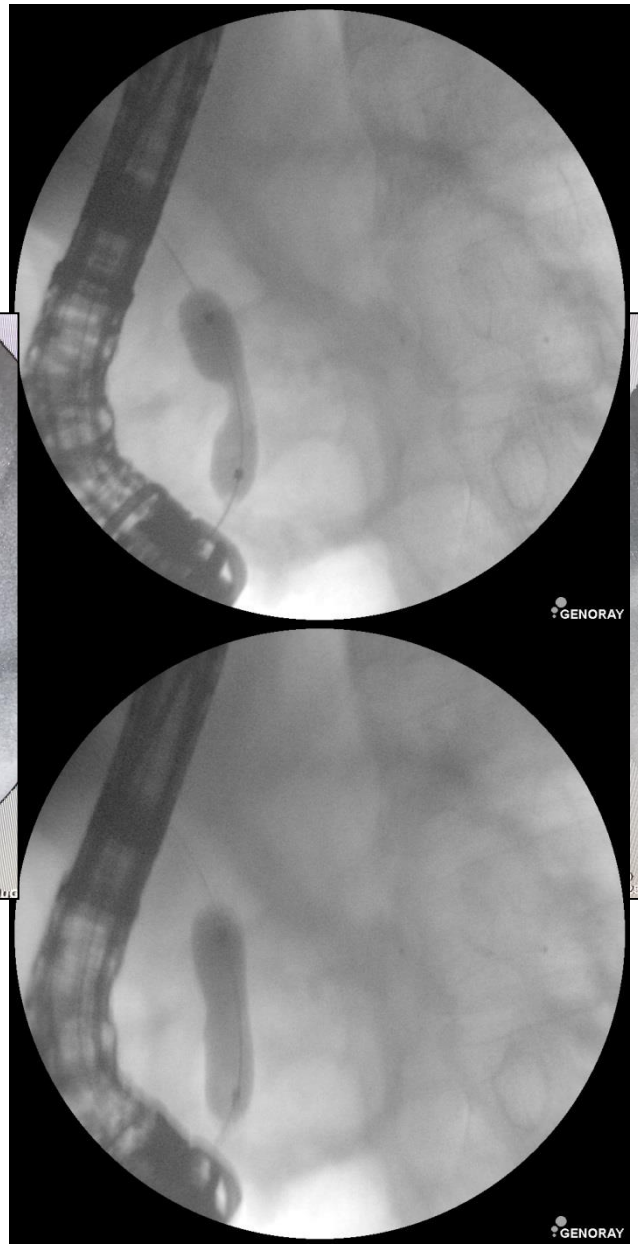
GENORAY
GENORAY

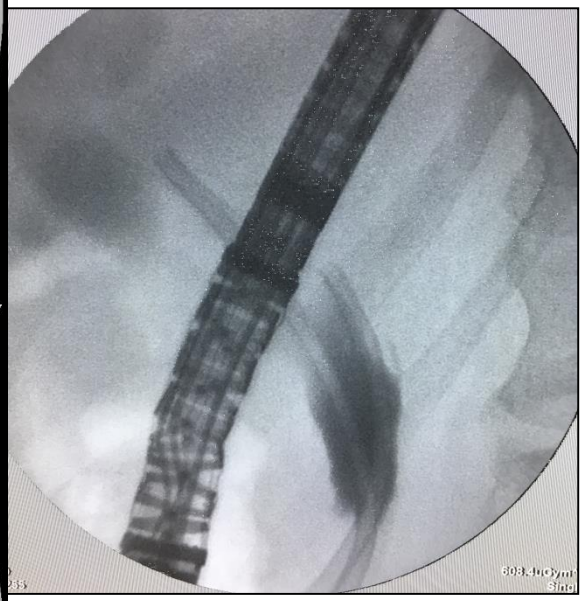

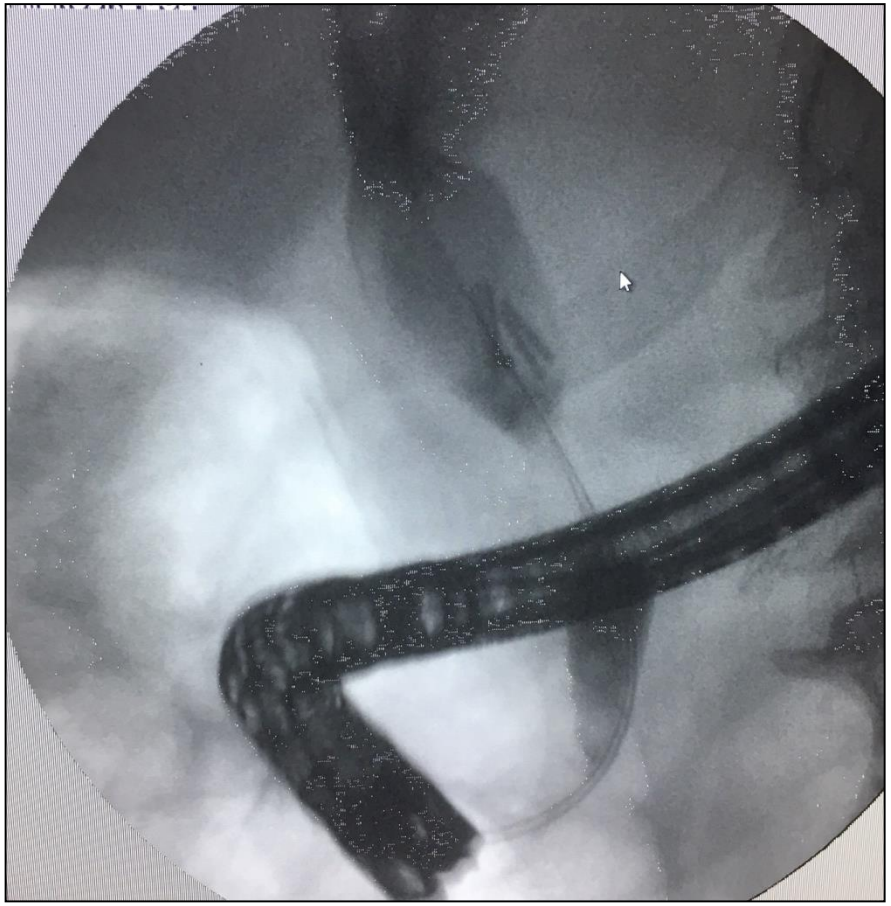

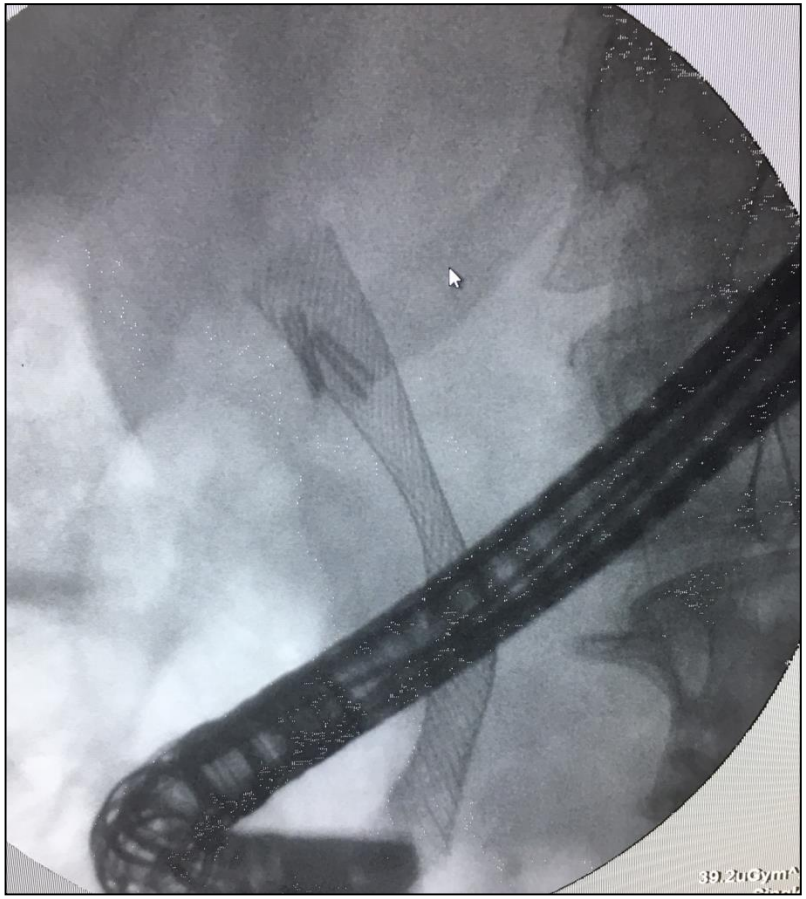

MALİGN BİLİYER DARLIKLAR

	Distal darlık	Hiler darlık
Preoperatif drenaj	Plastik stent (10F) Tam kaplı metal stent Kısa kapsız/parsiyel kaplı stent	
Unrezektabl hasta		

İşlem öncesi görüntüleme yöntemi ile karaciğer volümünün >%50'sini drene edecek segmentler saptanarak drene edildiğinde bilirubin >%50 azalır

MALİGN BİLİYER DARLIKLAR

	Distal darlık	Hiler darlık
Preoperatif drenaj	Plastik stent (10F) Tam kaplı metal stent Kısa kapsız/parsiyel kaplı stent	NBD (1-**2** adet) Perkütan drenaj Plastik stent
Unrezektabl hasta		

ROTATION

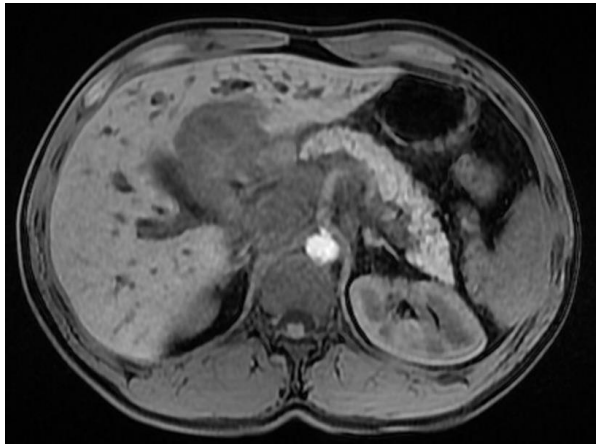

GENORAY

GENORAY

GENORAY



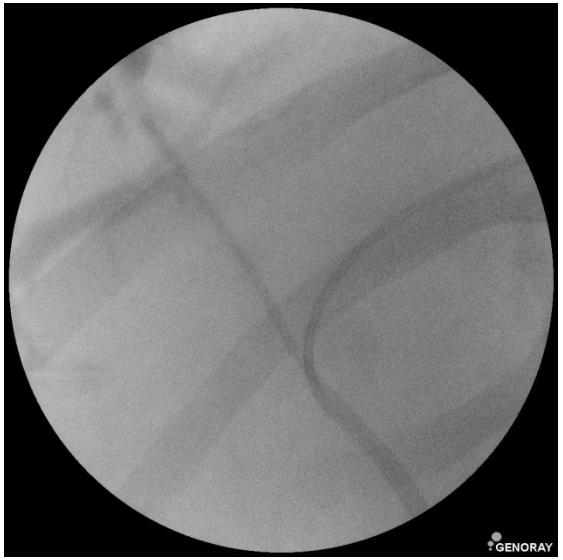
GENORAY

Rapor Grubu : Biyokimya
Numune Alım Tarihi : 07.08.2017 00:19:38
Numune Türü : Serum
Lab.Kabul Tarihi : 07.08.2017 00:49:16

Tetkik Adı	Sonuç		Normal Değer	Ünite
Glukoz	109	H	74 - 106	mg/dL
Üre	16	L	17 - 43	mg/dL
eGFR	121,27		- *	
Kreatinin	0,69		0,67 - 1,17	mg/dL
Ürik asit	2,3	L	3,5 - 7,2	mg/dL
ALT	256	H	0 - 50	U/L
AST	115	H	0 - 50	U/L
GGT	469	H	0 - 55	U/L
Alkalen fosfataz	762	H	30 - 120	U/L
Bilirubin (Total)	16,44	H	0,2 - 1,2	m
Bilirubin (Direkt)	8,59	H	0,00 - 0,20	
Bilirubin (İndirekt)	7,85		- *	
T.Protein	5,6			
Albümin	3,5		3,5 - 5,2	g/
Globulin	2,1		- *	

Cinsiyeti : E
Doğum Yeri : SAKARYA
Tanı : R10.4 - KARIN AĞRISI DİĞER VE TANIMLANMAMIŞ
İstem Yapan Doktor : Doç. Dr. KEREM KARAMAN
Özel Durumu : ----
Protokol No : 47425-17
Hasta Türü : YATAN HASTA

Barkod No: 6844955 - 18.08.2017 00:57:43
Rapor Grubu : Biyokimya (Acil)
Numune Alım Tarihi : 18.08.2017 01:13:15
Numune Türü : Serum
Lab.Kabul Tarihi : 18.08.2017 01:40:38
Onaylayan : AHMET DAĞ
Onay Tarihi : 18.08.2017 03:14:31
Çalışma Tarihi : 18.08.2017 02:33:17

Tetkik Adı	Sonuç		Normal Değer	Ünite	Açıklamalar	Eski Sonuçlar 17.08.2017 01:47:28	Eski Sonuçlar 16.08.2017 03:27:17
Glukoz	78		74 - 106	mg/dL		74	80
Üre	24		17 - 43	mg/dL		21	29
eGFR	132,14		- *			138,44	131,18
Kreatinin	0,56	L	0,67 - 1,17	mg/dL		0,5	0,57
Ürik asit	4,8		3,5 - 7,2	mg/dL		4,6	4,7
ALT	31		0 - 50	U/L		34	37
AST	26		0 - 50	U/L		29	29
GGT	112	H	0 - 55	U/L		125	119
Alkalen fosfataz	193	H	30 - 120	U/L		211	226
Bilirubin (Total)	3,34	H	0,2 - 1,2	mg/dL		3,71	4,36
Bilirubin (Direkt)	1,74	H	0,00 - 0,20	mg/dL		1,96	2,44
Bilirubin (İndirekt)	1,6		- *			1,75	1,92
T.Protein	5,4	L	6,6 - 8,3	g/dL		5,4	5,2
Albümin	2,6	L	3,5 - 5,2	g/dL		2,6	2,6
Globulin	2,8		- *			2,8	2,6
Sodyum (Na)	137		136 - 146	mmol/L		139	140
Potasyum	3,9		3,5 - 5,1	mmol/L		3,6	3,5
Klor (Cl)	100	L	101 - 109	mmol/L		103	
Kalsiyum (Ca)	8,2	L	8,8 - 10,6	mg/dL		7,8	

KarMed Bi
Aktif Hastaya

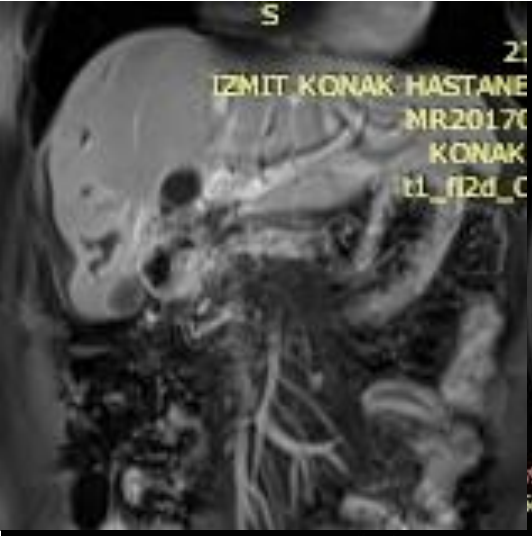

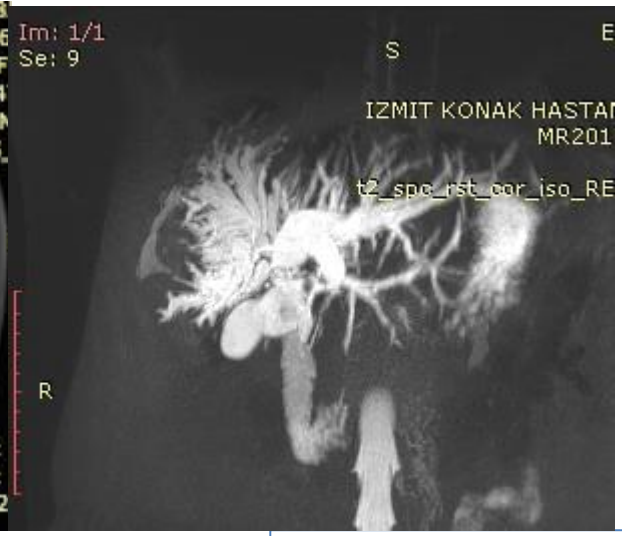

UNİLATERAL PLASTİK STENT

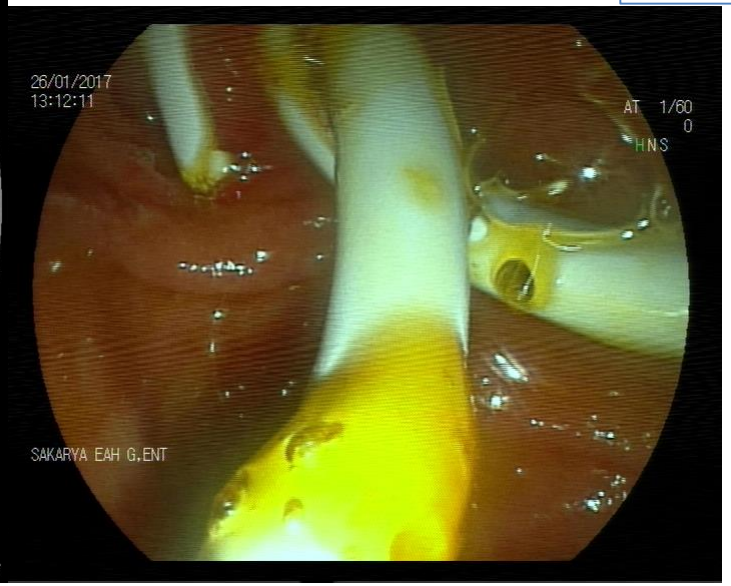

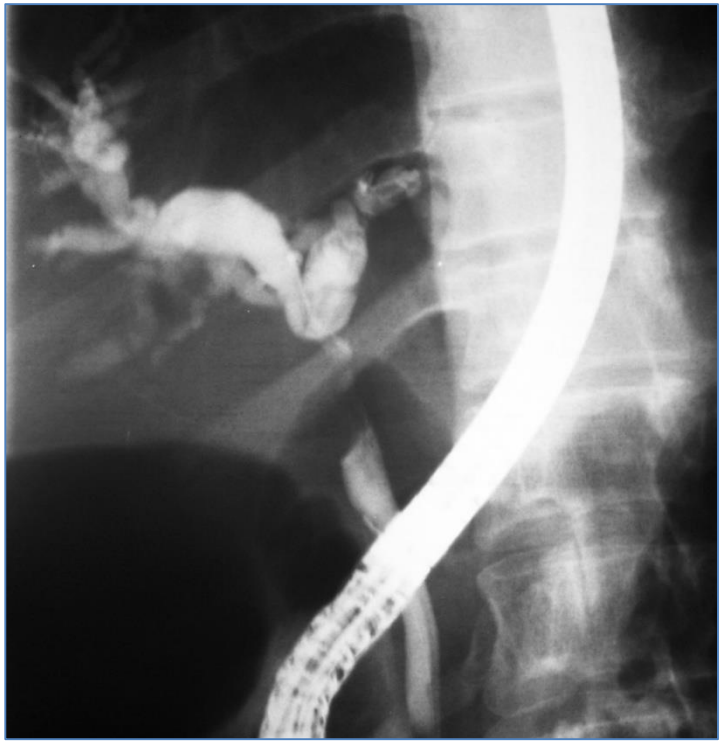

BİLATERAL
ENDOSKOPİK
PLASTİK

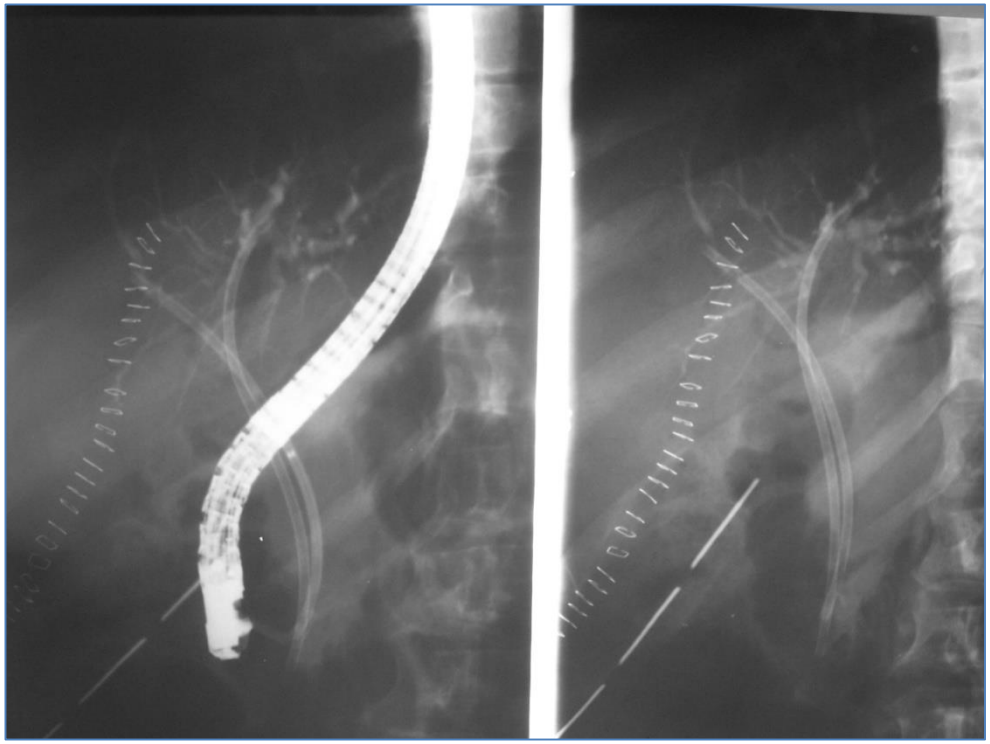

MALİGN BİLİYER DARLIKLAR

	Distal darlık	Hiler darlık
Preoperatif drenaj	Plastik stent (10F) Tam kaplı metal stent Kısa kapsız/parsiyel kaplı stent	NBD Perkütan drenaj Plastik stent
Unrezektabl hasta	Kapsız/parsiyel kaplı metal stent Plastik stent	

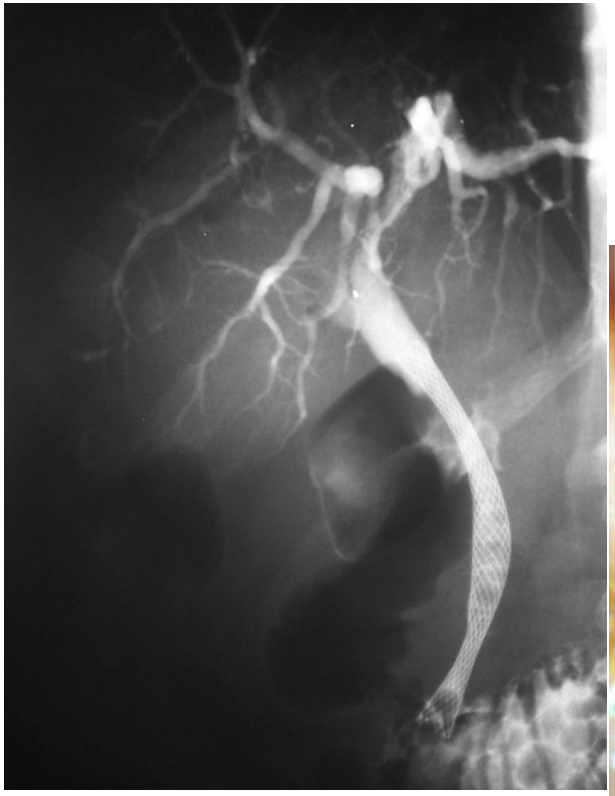

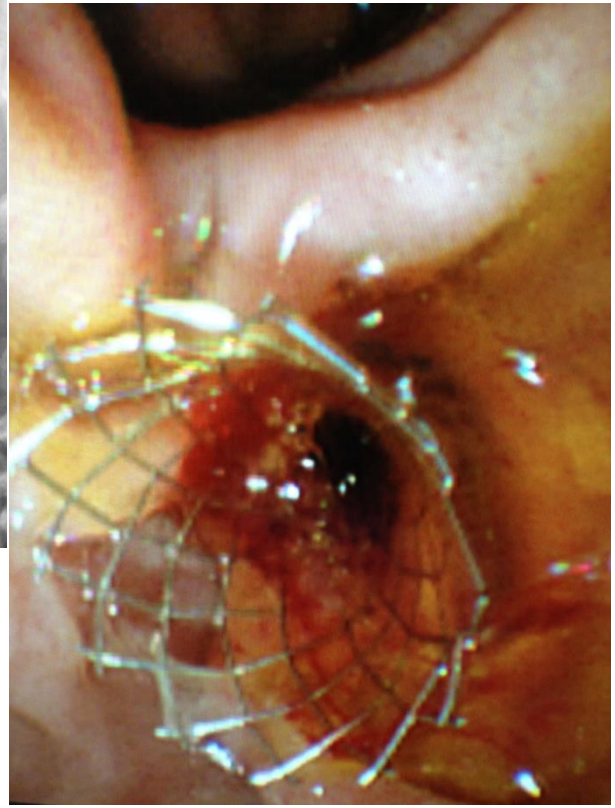

MALİGN BİLİYER DARLIKLAR

	Distal darlık	Hiler darlık
Preoperatif drenaj	Plastik stent (10F) Tam kaplı metal stent Kısa kapsız/parsiyel kaplı stent	NBD Perkütan drenaj Plastik stent
Unrezektabl hasta	Kapsız/parsiyel kaplı metal stent Plastik stent	Kapsız metal stent Plastik stent

HİLER
UNİLATERAL X BİLATERAL

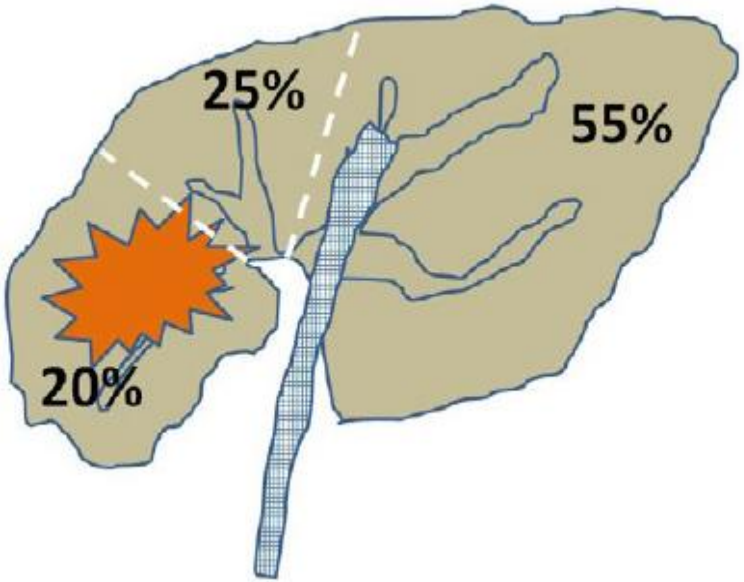

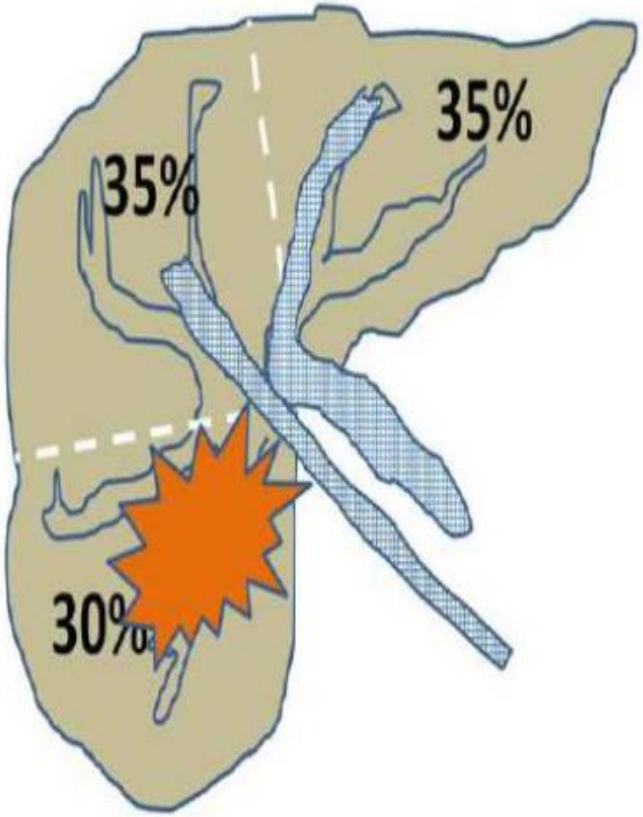

Prachayakul, J Gastroint Dig Syst 2014, 4:1

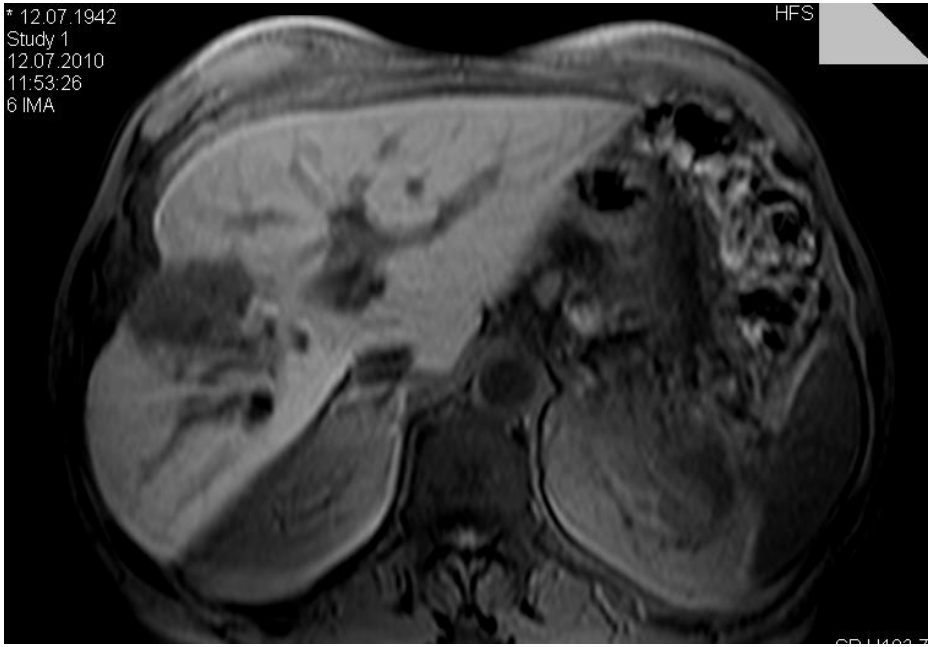

UNİLATERAL METAL STENT

BİLATERAL
YAN-YANA
ENDOSKOPİK

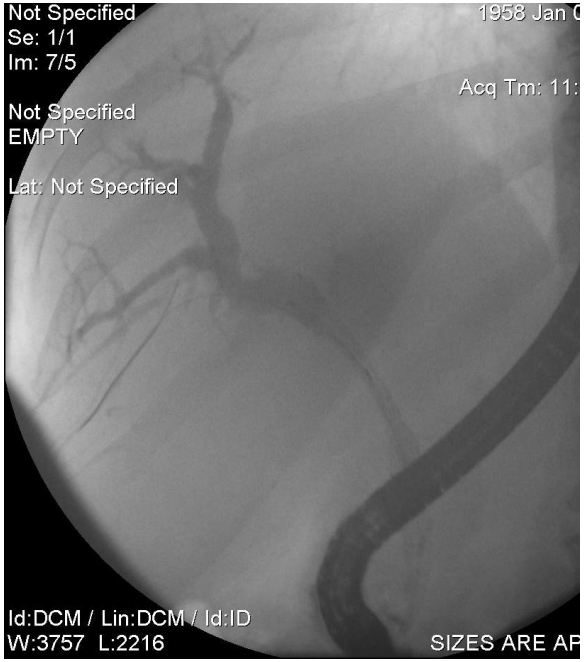

BİLATERAL
İÇ-İÇE ENDOSKOPİK
LARGE CELL STENT

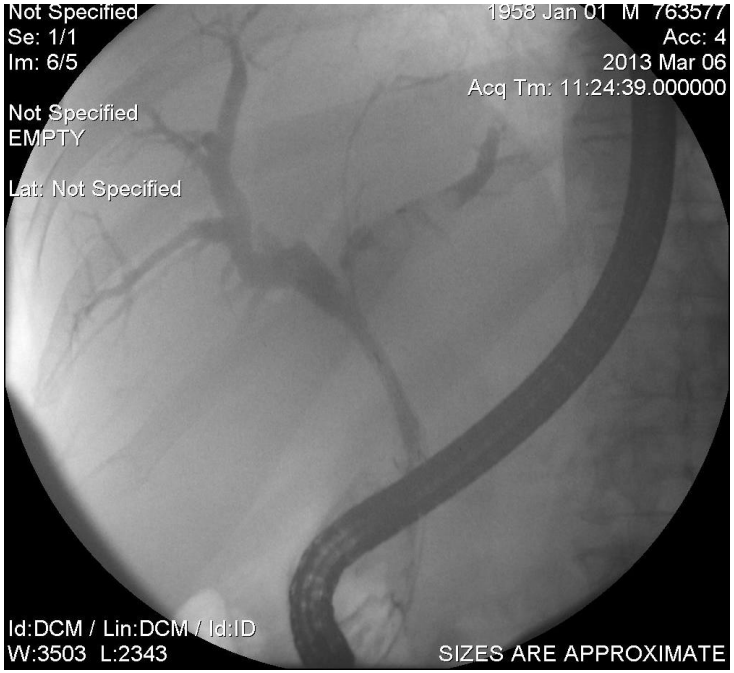

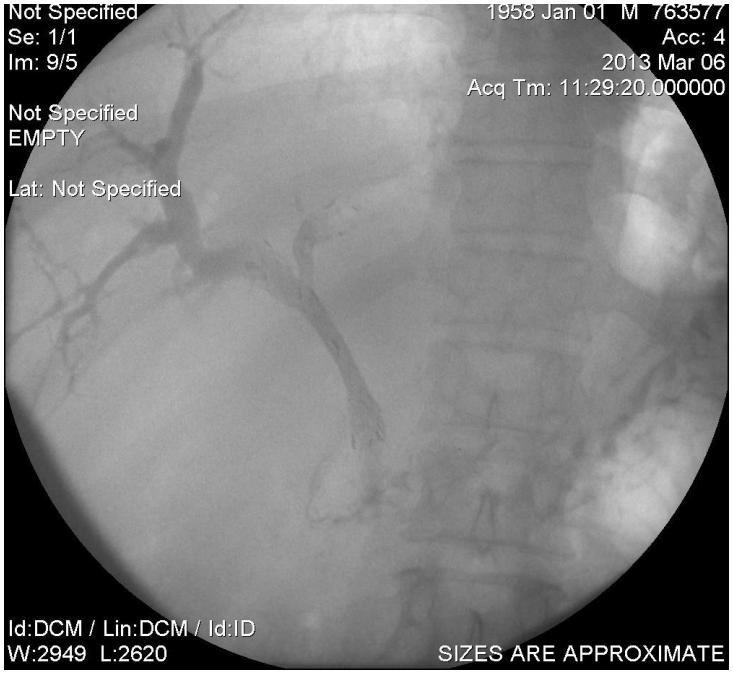

TÜRK KARACİĞER VAKFI
(www.tkcv.org)

AZERBAYCAN
TIP ÜNİVERSİTESİ

3 TÜRKİYE-AZERBAYCAN ORTAK HEPATOLOJİ KURSU
29-30 Eylül 2017, İstanbul